

## Successful combination therapy of low-dose aspirin and unfractionated heparin in recurrent pregnancy loss: A case report

Adhi Pribadi\*<sup>1</sup>

<sup>1</sup>Division of Maternalfetal, Department of Obstetrics and Gynecology, Universitas Padjadjaran, Bandung, Indonesia

Case Report

### ABSTRACT

#### ARTICLE INFO

##### Keywords:

Habitual Abortion,  
Aspirin, Heparin,  
Pre-eclampsia,  
Fetal Growth Restriction

##### \*Corresponding author:

priana1001@gmail.com

DOI: 10.20885/JKKI.Vol14.Iss1.art14

##### History:

Received: April 15, 2022

Accepted: February 7, 2023

Online: April 5, 2023

Copyright ©2023 Authors. This is an open access article distributed under the terms of the Creative Commons Attribution-NonCommercial 4.0 International Licence (<http://creativecommons.org/licenses/by-nc/4.0/>).

Habitual abortion, defined as more than two consecutive pregnancy losses, affects approximately 1% to 2% of women. This pathological condition undoubtedly frustrates a woman, yet this condition still has a chance to be treated and achieve a favorable pregnancy outcome. This case report aims to describe the success of a pregnancy with a history of recurrent miscarriages (five times of baby loss). The administration of a combination of low-dose aspirin and unfractionated heparin offers a 72-80% chance of having a good pregnancy outcome. We present a P2A5 woman with Thalassemia Minor and thrombocytosis. Preventive treatment, prenatal diagnosis, pregnancy outcomes, and complications were reviewed. Combination therapy of 80 mg aspirin and 2 x 5000 U unfractionated heparin subcutaneously during the last two pregnancies were able to maintain the pregnancy and prevent early pre-eclampsia or Fetal Growth Restriction (FGR) but not late-onset one. In the 6<sup>th</sup> pregnancy, the patient experienced late-onset FGR with a minor congenital anomaly. In the 7<sup>th</sup> pregnancy, severe pre-eclampsia appeared. However, administration of combination of heparin and aspirin could maintain pregnancy and fetal viability in Thalassemia Minor patients with recurrent abortus and thrombocytosis.

*Abortus habitualis adalah kondisi patologis yang dapat membuat frustrasi seorang wanita karena kehilangan kehamilan berulang kali, tetapi kondisi ini masih memiliki peluang untuk diobati dan mencapai kehamilan yang baik. Laporan kasus ini bertujuan untuk menggambarkan pemberian kombinasi aspirin dosis rendah dan heparin, untuk mempertahankan kehamilan pada kasus abortus habitualis. Abortus habitualis terjadi pada sekitar 1% hingga 2% wanita. Kombinasi aspirin dan heparin memiliki peluang 72%-80% untuk menghasilkan kehamilan yang sukses. Selain itu, untuk melihat jenis-jenis komplikasi kehamilan yang mungkin terjadi. Laporan kasus ini membahas seorang wanita P2A5 dengan thalassemia minor dan trombositosis. Upaya pencegahan, diagnosis prenatal, hasil kehamilan dan komplikasi yang timbul, akan ditinjau dan dibahas. Terapi kombinasi 80 mg aspirin dan pemberian injeksi unfractionated heparin dengan dosis 2 x 5000 U secara subkutan, selama 2 kehamilan terakhir dapat mencegah abortus, dan preeklamsia awitan dini atau pertumbuhan janin terhambat (PJT). Pada kehamilan ke-6, terdapat PJT awitan lambat dengan berat badan lahir bayi seberat 1900 g dengan terdapat kelainan ekstremitas club foot. Sementara itu, pada kehamilan ke-7 muncul pre-eklamsia berat. Kombinasi unfractionated heparin 2 x 5000 U dan 80 mg aspirin dapat mempertahankan kelangsungan hidup kehamilan dan janin. Pre-eklamsia dan PJT awitan lambat tidak dapat dicegah dengan kombinasi obat tersebut. Kombinasi heparin dan aspirin dapat mempertahankan kehamilan dan kelangsungan hidup janin pada pasien thalassemia minor dengan riwayat abortus berulang dan trombositosis.*

### INTRODUCTION

Recurrent pregnancy loss (RPL), or habitual abortion, was defined as three pregnancy losses,

consecutive or not, within 20 weeks of the last menstrual period, which affects approximately 1% to 2% of women.<sup>1</sup> The etiologic of RPL involves

immunological and blood component disorders, including antiphospholipid antibody syndrome (APS) and thrombophilia.<sup>2</sup> Sticky platelet syndrome (SPS) or platelet-hyper aggregation is associated with RPL and thrombophilia.<sup>3</sup> Besides, high platelet counts and hypercoagulable states may lead to thrombocytosis in thalassemia cases, thereby increasing the risk of thrombosis and possibly exacerbating thrombophilia.<sup>4</sup>

Heparin as a preventive therapy appears to have a beneficial effect on pregnancy outcomes in women with thrombophilia.<sup>5</sup> Combination therapy of heparin and aspirin before 12 weeks of gestation can prevent hypertension.<sup>6</sup> This case report discusses the success of using heparin in combination with aspirin in maintaining pregnancy for fetal survival in patients with minor Thalassemia accompanied by thrombophilia who have had recurrent miscarriages. In addition, to see pregnancy complications that may occur. The patient had permitted her health problem to be published.

#### CASE DESCRIPTION

We report two pregnancies in a 30-year-old woman with a history of 5 times abortions (POA5), with all previous abortions occurring before ten weeks gestation. Data were collected prospectively at the Maternalfetal Medicine Division High-Risk Pregnancy Clinic, Department of Obstetrics & Gynaecology, Padjadjaran

University, Bandung, Indonesia, from 2018 to 2020 (two pregnancies). The data described include laboratory results, preconception medication, preventive medication, prenatal diagnosis, pregnancy outcomes, and complications.

The pregnancy diagnosis was made at five weeks of gestation based on the last menstrual period. Several examinations included a complete blood test, anticardiolipin antigen antibodies, b-2 glycoprotein antibodies, liver and kidney function, and blood sugar. The previous test showed thyroid function within normal limits. Liver function, kidney function, and blood glucose levels were within normal limits. The Mean Corpuscular Volume (MCV) and Mean Corpuscular Haemoglobin (MCH) were below normal limits, and thrombocytosis, suspected Thalassemia, which then confirmed as Thalassemia Beta minor using hemoglobin electrophoresis (Table 1).

The presence of platelet hyper aggregation and thrombocytosis led to the decision to give a combination therapy of aspirin 80 mg and unfractionated heparin 2 x 5000 U per day subcutaneously. Based on the literature, Unfractionated heparin is equally effective and more affordable for the patient. We found fetal heart rate at the 7th week of gestation through transabdominal ultrasonography. At the 14th and 18th weeks, a Doppler examination revealed a notching on the bilateral artery uterine that was more pronounced on the left side (Figure 1).

Table 1. Laboratory result

Laboratory	Value	Note
Hemoglobin	11.0 mg/dl	Normal
Mean Corpuscular Volume*	62 fl	Abnormal
Mean Corpuscular Hemoglobin**	19.4 pg	Abnormal
Platelets***	488x103/ml	Abnormal
Ig M Anti Cardiolipin Antigen	1.2 Unit/ml	Normal
Ig G Anti Cardiolipin Antigen	2.0 Unit/ml	Normal
Ig M $\beta$ -2 Glycoprotein 1	1.2 Unit/ml	Normal
Ig G $\beta$ -2 Glycoprotein 1	2.5 Unit/ml	Normal
Hemoglobin A2****	4.7%	Abnormal
Ferritin	278 ng/ml	Normal
Platelets Hyperagregation	Positive	Abnormal

Note: Normal: \* > 80 fl, \*\* > 26 pg, \*\*\* < 450x103/ml, \*\*\*\* < 3.5%

In addition, unilateral mild clubfoot was detected. The patient then followed every month. From the 28<sup>th</sup> week of gestation onwards, biweekly growth monitoring was performed using ultrasound which showed a suboptimal fetal growth was not optimal. At the gestational age of 35 weeks, we discovered a late-onset FGR because of a stagnant fetal weight based on the growth chart on the ultrasound device compared to the previous week (Figure 2). An elective Cesarean section was planned five days after aspirin and heparin discontinuation 12 hours before the surgery. The newborn weighed 1900 g with a favorable APGAR score. We confirmed a

unilateral mild clubfoot, treated using a specific brace. The growth and development of the child were within normal limits.

Six months after delivery, 7<sup>th</sup> pregnancy was confirmed. The identical therapy was administered based on the history of previous successful pregnancy outcomes. Ultrasound of the uterine arteries in the 21<sup>st</sup> week showed notching on both sides, with a more pronounced left side (Figure 3)

Fetal growth looked good and optimal until the gestational age of 35 weeks and the fetal weight reached 2761 g. Delivery was planned at the 38<sup>th</sup> week by elective cesarean section

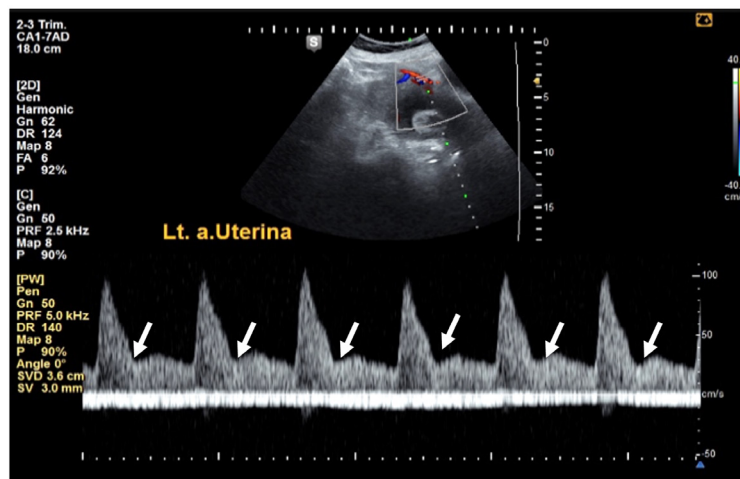


Figure 1. Left uterine artery. Ultrasound examination results for the 6<sup>th</sup> pregnancy, left uterine artery persistent notching at 18<sup>th</sup> weeks of pregnancy (white arrow).

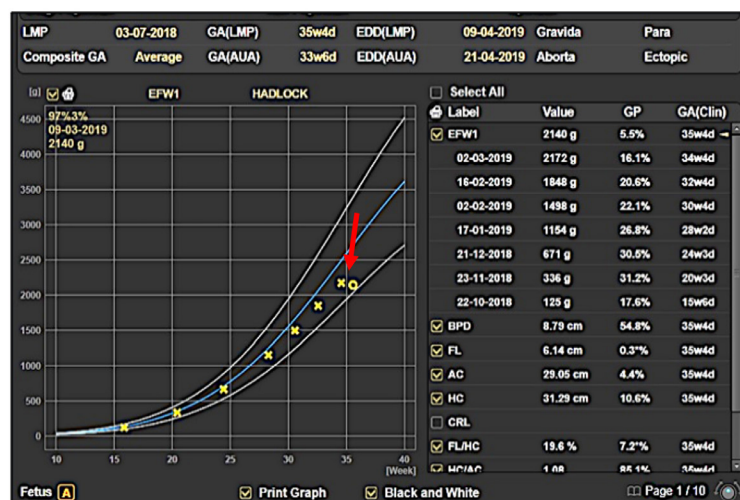


Figure 2. Growth chart. Ultrasound examination results for the 6<sup>th</sup> pregnancy. The fetal growth chart showed that fetal weight decreased at 35 weeks (red arrow).

following aspirin discontinuation at week 36, and heparin continued until 12 hours before delivery. We observed a new onset of hypertension and diagnosed the patient with severe (late onset) pre-eclampsia. The decision to terminate the pregnancy at 37<sup>th</sup> weeks is unavoidable. A healthy baby was born by cesarean section; the newborn's weight was 2800 g, with a good APGAR score and no congenital abnormalities. The mother and the newborn were discharged in healthy condition.

Figure 4 shows the survival resume of the last two pregnancies that managed to get a live baby even though the mother had pregnancy complications in the 3<sup>rd</sup> trimester, and the baby at 6<sup>th</sup> gestation had a mild clubfoot abnormality. Unlike the previous pregnancy, no congenital abnormality was seen in this 7<sup>th</sup> pregnancy.

**DISCUSSION**

Administration of heparin to pregnant women

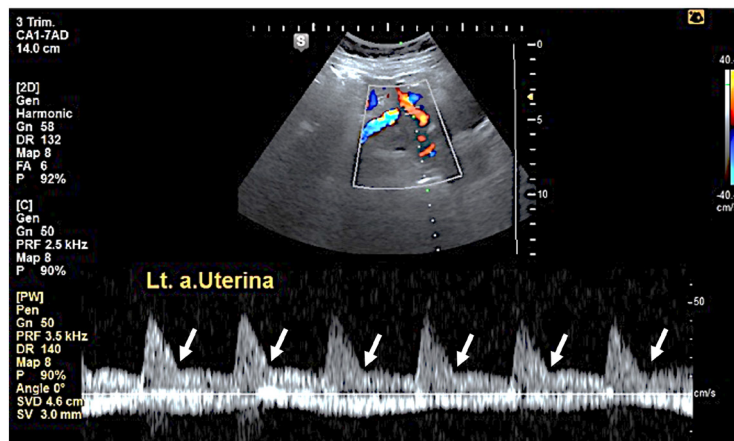


Figure 3. Left uterine artery. Ultrasound examination results for the 7<sup>th</sup> pregnancy, left uterine artery persistent notching at 21st weeks of pregnancy (white arrow).

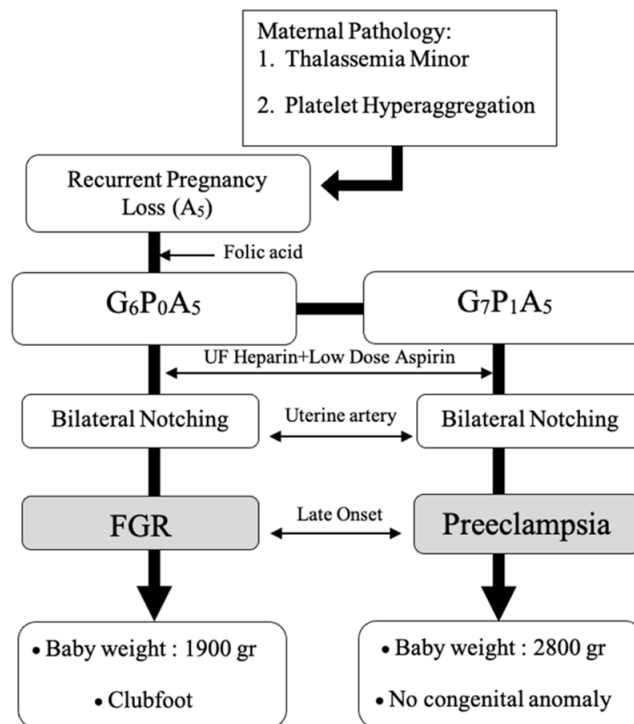


Figure 4. Management Algorithm

with thrombophilia in early pregnancy reduces the number of miscarriages, cases of FGR and Haemolysis, Elevated Liver Enzymes, and Low Platelets (HELLP) syndrome. However, the use of heparin does not affect Pre-Eclampsia incidence.<sup>7</sup> The combination of low-dose aspirin and heparin is superior to the use of aspirin only, with the combination of aspirin and heparin having a 72%-80% chance of having successful pregnancy outcomes.<sup>8</sup>

In these two pregnancies, the combination of heparin and low-dose aspirin was successful, resulting in delivery after 34 weeks of gestation with vigorous babies, although minor congenital abnormalities were found in the 6<sup>th</sup> pregnancy. Even though using similar treatment, two different types of complications arose in late pregnancy. In the 6<sup>th</sup> pregnancy, FGR appeared late in gestation, whereas the late onset of severe pre-eclampsia appeared in the 7<sup>th</sup> pregnancy. Low-dose aspirin is more effective in preventing the early onset of FGR and pre-eclampsia.<sup>9</sup> Aspirin only reduces the risk of early-onset pre-eclampsia when started before 16 weeks of gestation and at a daily dose of >100 mg; Meanwhile, the recommendation of the American College of Obstetricians and Gynecologists (ACOG) is 81 mg aspirin/day.<sup>10,12</sup> In this case, although the dose of aspirin administered was 80 mg, it prevented pre-eclampsia, probably because the treatment was given early in pregnancy and combined with heparin. The occurrence of abnormal MCV and MCH with a high platelet count is a condition that is often found in patients with Thalassemia.<sup>13</sup> Due to a tendency for thrombocytosis; therefore, low-dose aspirin alone is ineffective because of previous failed pregnancies. In the 6<sup>th</sup> pregnancy, laboratory values showed a platelet count of 488,000/mL, which indicated thrombocytosis. Pregnancy in patients with Thalassemia major or intermedia showed the dynamic multiple system changes and metabolic disturbances caused by chronic anoxia and iron overload. Those events are associated with an increased risk of thromboembolic events.<sup>14</sup> The first-trimester uterine artery can be used to predict newborns small for gestational age (SGA), especially early-onset SGA newborns.<sup>15</sup> During the 6<sup>th</sup> pregnancy, an ultrasound of the uterine arteries was performed at the 14<sup>th</sup> week and repeated at the 18<sup>th</sup> week showing a bilateral

notching with the left side more prominent. During the 7<sup>th</sup> pregnancy, the uterine arteries were examined at the 21<sup>st</sup> week and a bilateral notching with the left side was also more clearly observed. The notching appearance in the 2<sup>nd</sup> and 3<sup>rd</sup> trimesters of pregnancy indicated an increased uterine vascular resistance and impaired uterine circulation. Whereas in the first trimester, the notching in non-pregnant women was normal and should begin to disappear at 13 weeks until 16 weeks. Bilateral notching of the uterine artery assesses the risk of developing FGR or pre-eclampsia. In these cases, the combination of heparin and aspirin prevented the recurrent loss but did not prevent late-onset complications such as late-onset FGR and pre-eclampsia. The safety issue of aspirin use has been questioned for a long time, and it is a clinician's first consideration when deciding to administer aspirin early in pregnancy. In the 6<sup>th</sup> pregnancy, a minor congenital abnormality of clubfoot was found; it remains a question whether this is due to the administration of aspirin early in pregnancy. The meta-analysis by Kozler of receiving low-dose aspirin was not evidence of association with a congenital abnormality. Nevertheless, some literature reports an association with gastroschisis.<sup>16</sup> Clubfoot is associated with gene abnormalities, and repeated microduplication of chromosome 17q23.1q23.2 has been identified.<sup>17</sup> Diagnose parental clubfoot and smoking, confirm possible association with clubfoot in offspring, especially smoking in the first trimester.<sup>18</sup> Several genes are involved in the occurrence of clubfoot syndrome, particularly those affecting peroxisomal matrix proteins and enzymes required for the sulfation of proteoglycans, which are essential for connective tissue.<sup>19</sup> Further investigation is needed to confirm the association of clubfoot with aspirin. Meanwhile, heparin does not affect the fetus because it does not cross the placental barrier, so the frequency of occurrence is not different from normal pregnancy without heparin administration.<sup>20</sup> The limitations of this report are that we did not obtain accurate and complete medical and therapeutic data from 5 cases of abortion handled by previous clinicians. Therefore, all patients must always store medical data for future needs regarding previous medical conditions.

## CONCLUSION

The combination of 2 x 5000 U unfractionated heparin subcutaneously and 80 mg aspirin can maintain pregnancy and fetal viability especially when administered from early gestational age. However, late-onset pre-eclampsia and FGR cannot be prevented by using these drugs in combination. Thrombocytosis in pregnant patients aggravates platelet hyper aggregation, therefore a therapy combination is needed. Heparin and aspirin could maintain pregnancy and fetal viability in Thalassemia minor patients with recurrent abortus and thrombocytosis.

## CONFLICT OF INTEREST

None declared

## ACKNOWLEDGEMENT

None declared.

## REFERENCES

- Cao C, Bai S, Zhang J, Sun X, Meng A, Chen H. Understanding recurrent pregnancy loss: recent advances on its etiology, clinical diagnosis, and management. *Medical Review*. 2022;2(6): 570-589.
- El Hachem H, Crepaux V, May-Panloup P. Recurrent pregnancy loss: current perspectives. *International Journal of Womens Health*. 2017;9:331-45.
- Yagmur E, Bast E, Mühlfeld A, Koch A, Weiskirchen R, Tacke F, et al. High prevalence of sticky platelet syndrome in patients with infertility and pregnancy loss. *Journal of Clinical Medicine*. 2019;8(9):1328.
- Natesirinilkul R. Thromboembolism in beta-thalassemia disease. *Beta thalassemia* [Internet]. 2020 Sep 23; Available from: <http://dx.doi.org/10.5772/intechopen.89313>
- Skeith L, Carrier M, Kaaja R, Martinelli I, Petroff D, Schleußner E, et al. A meta-analysis of low-molecular-weight heparin to prevent pregnancy loss in women with inherited thrombophilia. *Blood*. 2016;127(13):1650-5.
- Van Hoorn ME, Hague WM, Van Pampus MG, Bezemer D, Ejog. 2016;160: DVJ. Low-molecular-weight heparin and aspirin in the prevention of recurrent early-onset pre-eclampsia in women with antiphospholipid antibodies: the FRUIT-RCT. *European Journal of obstetric, Gynecology and Reproductive Biology*. 2016;160:168-73.
- deAndrade J, Camargos M, deRezende R, Maciel R, Mello T, Batalha S. Heparin use in pregnant women diagnosed with thrombophilia: obstetric outcomes. *Clinics in Mother Child Health*. 2019;16(4): 331.
- Roberge S, Demers S, Nicolaides K, Bureau M, Côté S, Bujold E. Prevention of pre-eclampsia by low-molecular-weight heparin in addition to aspirin: a meta-analysis. *Ultrasound in Obstetrics and Gynecology*. 2016;47(5):548-53.
- Lan P, Gillin A, Pelosi M, Tooher J, Sandager P, Hyett J. Effect of early use of low-dose aspirin therapy on late-onset pre-eclampsia. *Journal of Maternal-Fetal and Neonatal Medicine*. 2019;32(13):2137-42.
- Roberge S, Bujold E, . N. Aspirin for the prevention of preterm and term pre-eclampsia: systematic review and metaanalysis. *American Journal of Obstetric and Gynecology*. 2018;218(3);287-93.
- Ghazanfarpour M, Sathyapalan T, Banach M, Jamialahmadi T, Sahebkar A. Prophylactic aspirin for preventing pre-eclampsia and its complications: An overview of meta-analyses. *Drug discovery Today*. 2020;25(8):1487-1501.
- ACOG Committee Opinion No. 743: Low-dose aspirin use during pregnancy. *Obstetrics and Gynecology*. 2018;132(1):e44-e52.
- Pribadi A, Mose J, Effendi J. MCV-MCH value and one tube osmotic fragility test (OTOFT) method for thalassemia trait detection in pregnancies. *Medicine Science*. 2016;5:384-92.
- Petrakos G, Andriopoulos P, Tsironi M. Pregnancy in women with thalassemia: challenges and solutions. *International Journal of Women's Health*. 2016; 8:441-51.
- Drouin O, Boutin A, Paquette K, Gasse C, Guerby P, Demers S, et al. First-trimester uterine artery Doppler for the prediction of SGA at birth: The Great Obstetrical Syndromes Study. *Journal of Obstetric and Gynecology Canada*. 2018;40(12):1592-9.
- Sun S, Qian H, Li C. Effect of low dose aspirin application during pregnancy on fetal congenital anomalies. *BMC Pregnancy and Childbirth*. 2022; 22:802
- Alvarado D, Aferol H, McCall K, Huang J, Techy

- M, Buchan J, et al. Familial isolated clubfoot is associated with recurrent chromosome 17q23.1q23.2 microduplications containing TBX4. *The American Journal of Human Genetic.* 2010 ;87(1):154-60.
18. Dodwell E, Risoe P, Wright J. Factors Associated With Increased Risk of Clubfoot: A Norwegian National Cohort Analysis. *Journal of Pediatric Orthopaedics.* 2015;35(8):e104-e109.
  19. Sadler B, Gurnett CA, Dobbs MB. The genetics of isolated and syndromic clubfoot. *Journal of Children's Orthopaedics.* 2019 Jun 1;13(3):238-244.
  20. Ginsberg J, Kowalchuk G, Hirsh J, Brill-Edwards P, Burrows R. Heparin therapy during pregnancy. Risks to the fetus and mother. *Archives of Internal Medicine.* 1989;149(10):2233-6.