

Testosterone undecanoate treatment for muscle weakness in a male with hypogonadotropic hypogonadism delayed puberty: A case report

Dicky Moch Rizal^{*1,2}, Nandia Septiyorini¹

¹Department of Physiology, Faculty of Medicine, Public Health, and Nursing, Universitas Gadjah Mada, Yogyakarta, Indonesia

²Andrology Outpatient Clinic, Sadewa Mother and Child Hospital, Yogyakarta, Indonesia

Case Report

ABSTRACT

ARTICLE INFO

Keywords:

delayed puberty, hypogonadotropic hypogonadism, testosterone undecanoate, muscle weakness

*Corresponding author:

drdickyandrologi@ugm.ac.id

DOI: 10.20885/JKKI.Vol13.Iss2.art14

History:

Received: March 21, 2022

Accepted: August 23, 2022

Online: August 31, 2022

Copyright ©2022 Authors.

This is an open access article distributed under the terms of the Creative Commons Attribution-NonCommercial 4.0 International Licence (<http://creativecommons.org/licenses/by-nc/4.0/>).

Puberty is a series of physical development and sexual maturation that aims to achieved reproductive capacity. The hypothalamic-pituitary-gonadal (HPG) axis has an important role in the normal process of puberty. Disruption in the HPG axis causes hormonal disturbances, one of which is hypogonadotropic hypogonadism, which is associated with delayed puberty. Hormonal disorders can also cause various problems besides the reproductive system, such as muscle weakness, lack of energy, and an increased risk of bone fractures. We report the case of a male patient who complained of predominant muscle weakness, did not show signs and symptoms of puberty, and had an idiopathic hypogonadotropic hypogonadism who unresponsive to human chorionic gonadotropin (hCG) therapy. We decided to administered Testosterone Undecanoate (TU) therapy to overcome the problem of delayed puberty and complaints of muscle weakness experienced by the patient. TU therapy has shown beneficial effects in these patients by increasing testosterone levels, increasing penis length, and eliminating complaints of muscle weakness.

Pubertas merupakan serangkaian proses perkembangan fisik dan maturasi seksual sehingga dapat tercapai kapasitas reproduksi. Aksis hipotalamus-pituitari-gonadal (HPG) memiliki peran penting dalam keberlangsungan proses normal pubertas. Gangguan pada kerja aksis HPG menyebabkan gangguan hormonal salah satunya hipogonadotropik hipogonadisme yang berkaitan dengan pubertas tertunda. Gangguan hormonal juga dapat menyebabkan berbagai keluhan di luar sistem reproduksi, seperti kelemahan otot, kekurangan energi, dan peningkatan risiko fraktur tulang. Kami melaporkan kasus pasien pria dengan keluhan kelemahan otot yang dominan, tidak menunjukkan kemunculan tanda dan gejala pubertas, dan mengalami kondisi hipogonadotropik hipogonadisme idiopatik yang tidak berespon terhadap terapi human chorionic gonadotropin (hCG). Terapi Testosteron Undecanoate (TU) diberikan untuk mengatasi masalah keterlambatan pubertas dan keluhan kelemahan otot yang dialami pasien. Terapi TU telah menunjukkan efek menguntungkan pada pasien ini dengan meningkatkan kadar testosteron, meningkatkan panjang penis, dan menghilangkan keluhan kelemahan otot.

INTRODUCTION

Puberty is a series of physical development and sexual maturation in humans under

neuroendocrine control that aims to achieve reproductive capacity.^{1,2} The hypothalamic-pituitary-gonadal (HPG) axis has a critical role in

pubertal development and reproductive system maturation. The onset of puberty is manifested by an increase in GnRH neurons activity leading to a pulsatile release of luteinizing hormone (LH) and follicle stimulation hormone (FSH) secretion.³⁻⁵ LH is responsible for supporting the Leydig cell-mediated testicular endocrine function which has a major role in the development and differentiation of male reproductive genitalia.⁶ While FSH is responsible for supporting the activity of the Sertoli cells in the process of spermatogenesis.⁷ Testicular enlargement is an early sign of puberty in males, accompanied by the development of other secondary sexual characteristics such as the growth of pubic, face, and body hair, changes in voice, increased muscle mass, increased penile length, experience nocturnal emission, changes in body composition, and growth spurts.^{8,9}

The HPG axis disorders, both congenital and acquired, lead to impaired reproductive function and the clinical syndrome of hypogonadism. Decreased testicular activity accompanied by decreased androgen production is closely related to male hypogonadism.¹⁰ The prevalence of hypogonadism varies by age group, but it is estimated that 2.1% to 38.7% of the middle to the older male population affected by hypogonadism.^{11,12} Hypogonadism can be caused by both testicular pathology (primary hypogonadism/ hypogonadotropic hypogonadism) and hypothalamic and/or pituitary failures (secondary hypogonadism/ hypogonadotropic hypogonadism) which are related to genetic disorder and malignancy.⁵ Primary hypogonadism is biochemically characterized by low levels of testosterone and high levels of gonadotropin hormone. While secondary hypogonadism/ hypogonadotropic hypogonadism showed a low level of both testosterone and gonadotropin hormone.¹³

Hypogonadism is associated with delayed puberty which is manifested by the absence of secondary sexual characteristics at the age of 2-2.5 standard deviations above the mean age in the population. Delayed puberty in males is diagnosed when there is no increase in testicular volume at the age of 14.¹ It

is affected approximately 2% adolescent population, with one of the contributing factors being hypogonadotropic hypogonadism.¹⁴ Several problems that occur in addition to the reproductive system due to low testosterone levels include fatigue, decreased muscle mass, muscle weakness, decreased physical performance, and an increase in the risk of bone fracture.^{15,16}

Testosterone therapy in cases of hypogonadism aims to induce and maintain the development of secondary sexual characteristics and manage the symptoms of testosterone deficiency experienced by the patient.¹⁷ The use of Testosterone Undecanoate (TU) as a therapeutic option in patients with hypogonadism has shown various benefits. The chemical structure of TU makes it have a longer half-life than other types of testosterone, so patients don't need to get injections too often. This makes TU therapy more time- and cost-efficient and can reduce patient discomfort during the injection procedure.^{18,19} We report the case of a man with complaints of predominant muscle weakness with delayed puberty due to hypogonadotropic hypogonadism who received TU therapy.

CASE DESCRIPTION

A 21-year-old male patient came to our andrology outpatient clinic complaining of underdeveloped genitalia. This patient also complains of muscle weakness, lower running strength than other men at his age, and lack of energy. The patient stated that he was very disturbed by this condition because he was going to do a military selection. The patient previously went to a specialist doctor and received testosterone injections, (Sustanon 250, contains testosterone propionate, testosterone phenylpropionate, testosterone isocaproate and testosterone decanoate) three times every two weeks. The patient reports no change after the injection, both clinically in the genital organs and in physical performance.

Based on the physical examination's results, it is known that body weight and body heights were 56 kg and 171 cm respectively, with body

mass index (BMI) 19.2 which are categorized as normal BMI according to the Ministry of Health of the Republic of Indonesia's classification. The patient reported no decreased sense of smell (hyposmia) or anosmia, showed normal arm and leg proportions, and presented a non-gynaecoid pelvis. Genital examination was carried out and the results of the testicular volume were 2 cc/ 2 cc with a penis length of 3 cm. There were no clinical signs of varicocele, normal scrotal skin pigmentation corresponds to the skin of the thighs, and no female pattern pubic hair growth was found. No facial and body hair, no gynecomastia, and no central obesity. The high-pitched voice was identified in the patient and no signs of development of secondary sexual characteristics were found.

The patient underwent hormonal examination with the results of testosterone levels 204.3 ng/dL (normal range: 249-836 ng/dL using ECLIA method), FSH levels 0.2 mIU/ml, and LH levels <0.03 IU/L. Based on the results of the examination, we diagnosed the patient as having delayed pubertal hypogonadotropic hypogonadism with predominant muscle weakness. We decided to administer an injection of human chorionic gonadotropin (hCG) 250 µgrams as an induction therapy which aim to assess the Leydig cell response to produce testosterone. The hormonal evaluation has been done five days after the hCG injection with the result of testosterone level 153.8 ng/dL (normal range: 249-836 ng/dL using ECLIA method) which indicate no improvement compared to before hCG injection.

Based on the lower testosterone level than before the hCG injection, it was decided to administer a re-injection of hCG 250 µgrams to confirm the hCG response and evaluate the testosterone level three days after injection. Based on the results of hormonal examination, testosterone levels were found to be 184 ng/dL (normal range: 249-836 ng/dL using ECLIA method). This result was unfavorable (still below the normal range), considering that the examination was carried out only 3 days after the hCG injection. The expected testosterone level is twice as high as the initial testosterone level before the injection. Economically the patient requires a very high cost, making it burdensome to inject hCG in larger doses and for a longer period of time (patients are recommended to inject hCG three times a week to achieve normal testosterone levels).

Ultrasound examination is conducted to confirm the results of the physical examination and investigate the other causes of failure of hCG induction therapy. Based on the testicular ultrasonography (Figure 1) it was identified the size of the right testis 1.6 x 0.9 x 1.29 cm with the regular surface, normal parenchymal echostructure, no cystic or solid lesions, and no intratesticular calcifications.

Meanwhile, the size of the left testis was 1.47 x 0.67 x 1.42 cm with the regular surface, normal homogeneous parenchymal echostructure, no cystic or solid lesions, and no intratesticular calcification. Bilateral testicular atrophy was identified without bilateral varicocele or hydrocele (Figure 2).

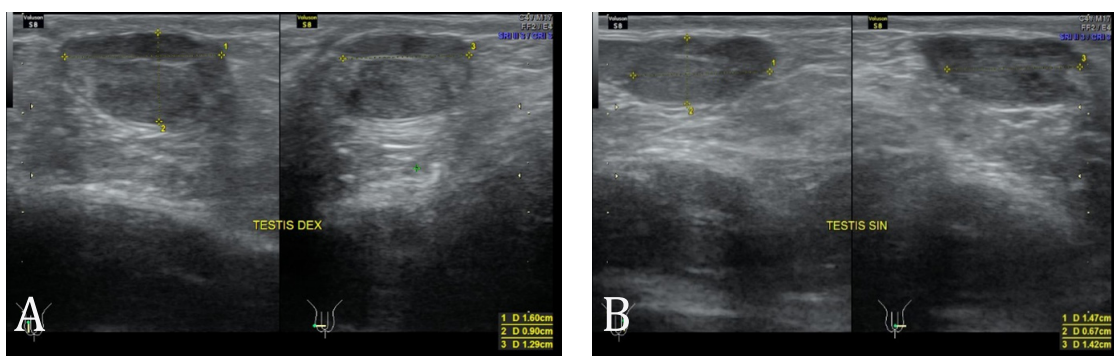


Figure 1. A) Right testicular size; B) Left testicular size

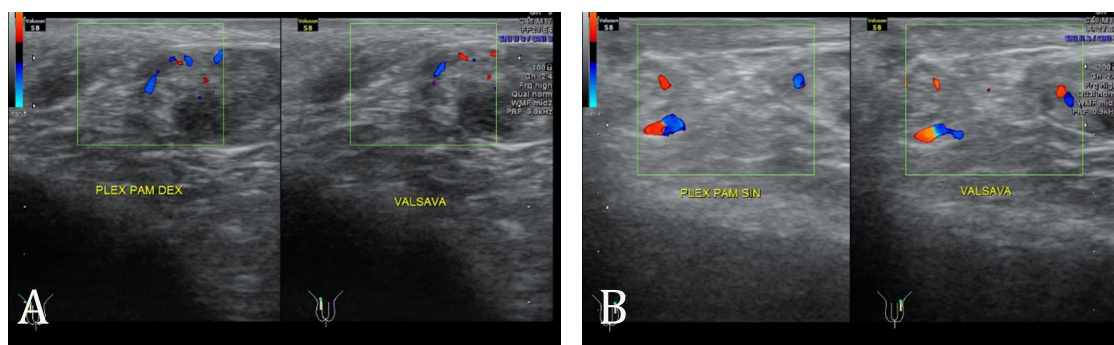


Figure 2. No identified of varicocele or hydrocele in the right testicle (A) and left testicle (B)

As the patient did not respond to hCG therapy, testosterone undecanoate (TU) injection (Nebido® 1000 mg) was considered. An evaluation of testosterone levels was carried out six weeks after the first TU injection. Testosterone levels increase to 6.11 ng/mL (normal range: 2.27-10 ng/mL using ELFA method) and the patient reported that there was no muscle weakness, erections become more frequent, penis length increases, but there is no change in testicular volume. The patient undergone testosterone evaluation examination four months after the first injection with the result was 4.08 ng/mL (normal range: 2.27-10 ng/mL using ELFA method) and followed by the second TU injection.

Informed consent has been obtained from the patient as a form of agreement that the case can be published by ensuring the confidentiality of the patient's identity. Ethical clearance was obtained from the Medical and Health Research Ethics Committee (MHREC) Faculty of Medicine, Public Health, and Nursing Universitas Gadjah Mada-DR. Sardjito General Hospital (Ref. No.: KE/FK/0424/EC/2022)

DISCUSSION

We presented case of a male diagnosed with hypogonadotropic hypogonadism delayed puberty with predominant muscle weakness. Based on the results of the physical examination, it was found that the patient did not develop testicular volume, small penis, pubic hair did not grow, and high-pitched voice. This indicates that the patient has delayed puberty, even though

the patient's body posture is normal for his age. This condition is confirmed by the results of hormonal examinations which show low levels of testosterone and gonadotropins. Delayed puberty is a condition where no signs of puberty are found at the age of 2-2.5 standard deviations above the mean age and affected approximately 2% of adolescents. Hypogonadotropic hypogonadism is known to be one of the factors contributing to this condition.¹⁴

The patient presented normal proportion of legs and arms, non-gynaecoid pelvis, no female pattern pubic hair growth with low FSH. Suspicion of Klinefelter syndrome was dismissed even though the patient showed hypogonadism. Klinefelter syndrome is one of the most common chromosomal abnormalities in hypogonadism which can result in several conditions such as osteoporosis, fractures, and neoplasia.²⁰ The patient did not experience a decrease in the sense of smell (hyposmia or anosmia) as the major manifestation in Kallmann syndrome, even though hormonal examination shows the result of hypogonadotropic hypogonadism.²¹ In addition, the patient's posture appeared normal, the BMI was categorized as normal, and did not show gynecomastia. Based on the results of these examinations, the suspicion of Kallmann syndrome was also eliminated.

Based on the results of the physical and hormonal examinations that have been carried out, as well as dismissing for the diagnosis of Klinefelter syndrome and Kallmann syndrome, we conclude that the patient has Idiopathic Hypogonadotropic Hypogonadism (IHH).

Generally, IHH is divided into two categories: Kallmann syndrome (KS) and normosmic IHH (nIHH), and can be congenital or acquired. This patient did not experience the typical sign of Kallmann syndrome, namely anosmia, so it was categorized in the nIHH. In the case of IHH, the major manifestation observed is a pubertal delay, that is in accordance with the conditions experienced by patients who do not show signs of puberty.²² The prevalence of IHH is not widely studied, it is estimated that 1-10 cases of IHH are found in every 100,000 births, with 40% of cases being nIHH.²³

Human chorionic gonadotropin (hCG) injection of 250 µgrams is administered to patient which aims to assess the ability of Leydig cells to produce testosterone. In cases of hypogonadotropic hypogonadism, androgen therapy is carried out in two ways: exogenous testosterone replacement and induction of endogenous testosterone production through the administration of hCG.²⁴ The results of the hormonal evaluation show lower testosterone levels than before the hCG injection, this is thought to be a testicular failure to produce testosterone. We consider giving Testosterone Undecanoate (TU) preparations to the patient based on the previous testosterone preparations administration that did not show clinical improvement or reduce the complaints of muscle weakness and lack of energy experienced by the patient. In the previous testosterone preparations administration, no signs of virilization were identified, there was no increase in penis length, nor an increase in testicular volume. This may occur because the previous administration of testosterone does not meet the recommended dose, so it is not strong enough to stimulate virilization and growth of the genital organs. In the previous testosterone administration, hormonal examinations were not carried out to evaluate the response of therapy.

Administration of TU to young men is indicated in cases of hypogonadism which aims to induce puberty.²⁵ Based on the previous study, a long-acting injectable TU administration showed a safety profile and can maintain stable

testosterone level only in four times injection continuously.²⁶ TU has an 11-carbon side chain which can prolong its half-life compared to testosterone cypionate or enanthate. This TU depot injection allows the patient to receive less testosterone injections so that it is more cost-effective, time-efficient, and comfortable for the patient.¹⁹ In addition, TU as a type of long-acting formulation of testosterone, will improved the biochemical response than the short-acting ones. The administration of TU also did not show extreme fluctuations in testosterone levels, considering that these fluctuative levels changes can cause symptomatic distress for patients.¹⁸

Physical condition monitoring was carried out on this patient and it was identified that there was a process of virilization and an increase in penile length after TU injection. A previous study by Eisenberg et al. stated that an increase in testosterone levels was correlated with an increase in penile length.²⁷ Liu et al. conducted a study on boys with micropenis who received TU therapy, to determine its effect on the increase of penile length. In this study, TU was orally administered with consideration of uncommon injection administration in children. The results showed that after 3-9 months of therapy, penile length was obtained, and the safety and effectiveness of administering TU were identified in children with micropenis.²⁸ The patient also reported that the muscle weakness and lack of energy had disappeared after the first TU injection. The meta-analysis study conducted by Skinner et al. showed that administration of testosterone therapy via intramuscular injection had an effect on increasing total body strength by 11.2%, increasing lower extremity strength by 10.4%, and increasing upper extremity strength by 12.9%. This finding suggests that intramuscular administration of testosterone therapy has a 3-5 times greater effect on increasing muscle strength compared to transdermal administration.²⁹

The results of the examination of testosterone levels carried out six weeks after the first TU injection showed an increase from 184 ng/dL to 6.11 ng/mL (611 ng/dL). The second injection

was carried out 4 months after the first injection, followed by an evaluation of testosterone levels which showed a decrease from 6.11 ng/mL to 4.08 ng/mL. The decrease in testosterone levels that occurred was still within the normal range based on the reference value set by the hormonal testing laboratory, which was in the range of 2.27-10 ng/mL by the ELFA method. Administration of TU to this patient was proven to be able to overcome the problem of delayed puberty observed by the improvements in the virilization process and increasing penile length. Complaints of muscle weakness and lack of energy experienced by the patient disappeared after the first TU injection.

The use of various testosterone therapy to treat muscle problems has been reported in several previous studies. Study by Dias et al. stated that giving 5 grams of transdermal testosterone gel (TT) for 12 months can improve the lumbar spine bone mineral density and knee muscle strength in the elderly.³⁰ A meta-analysis study by Skinner et al. showed a result that administration of testosterone therapy via the intramuscular route has proven more effective in improving muscle strength in middle-aged and older men, especially in the lower extremity.³¹ Wood et al. conducted a study to determine the effect of testosterone therapy in cases of Duchenne muscular dystrophy (DMD) and delayed puberty. DMD is one of the most common muscular dystrophies in childhood. In this study, participants stated that there was an increase in body strength, grown of the height, and deeper voice after injection of testosterone therapy.³² These studies support the use of testosterone therapy in treating muscle weakness problems in male patients with hypogonadism delayed puberty.

CONCLUSION

Idiopathic hypogonadotropic hypogonadism (IHH) is a rare condition in the population. In this case, the patient had normosmic IHH (nIHH) with complaints of muscle weakness and showed no signs of secondary sexual characteristic development. hCG therapy did not show a

good response to the complaints experienced by the patient so he was considered to give a TU injection. The evaluation examination results show that TU is effective in increasing testosterone levels, eliminating complaints of muscle weakness, and developing secondary sexual characteristics.

CONFLICT OF INTEREST

The authors report no conflict of interest.

ACKNOWLEDGEMENT

We are thankful to all those who offered excellent technical help during the study.

REFERENCES

1. Bozzola M, Bozzola E, Montalbano C, Stamatii FA, Ferrara P, Villani A. Delayed puberty versus hypogonadism: A challenge for the pediatrician. *Annals of Pediatric Endocrinology and Metabolism*. 2018;23(2):57-61.
2. Plant TM. Neuroendocrine control of the onset of puberty. *Frontiers in neuroendocrinology*. 2015;38:73-88.
3. Lomniczi A, Ojeda SR. The emerging role of epigenetics in the regulation of female puberty. *Endocrine development*. 2016;29:1-16.
4. Spaziani M, Tarantino C, Tahani N, Gianfrilli D, Sbardella E, Lenzi A, et al. Hypothalamo-Pituitary axis and puberty. *Molecular and cellular endocrinology*. 2021;520:111094.
5. Salonia A, Rastrelli G, Hackett G, Seminara SB, Huhtaniemi IT, Rey RA, et al. Paediatric and adult-onset male hypogonadism. *Nature Reviews Disease Primers*. 2019;5(1):38.
6. Flück CE, Meyer-Böni M, Pandey AV, Kempná P, Miller WL, Schoenle EJ, et al. Why boys will be boys: Two pathways of fetal testicular androgen biosynthesis are needed for male sexual differentiation. *American journal of human genetics*. 2011;89(2):201-18.
7. Ross A, Bhasin S. Hypogonadism: Its prevalence and diagnosis. *The Urologic clinics of North America*. 2016;43(2):163-76.
8. Abreu AP, Kaiser UB. Pubertal development

- and regulation. *Lancet Diabetes Endocrinol.* 2016;4(3):254-64.
9. Marshall WA, Tanner JM. Variations in the pattern of pubertal changes in boys. *Archives of disease in childhood.* 1970;45(239):13-23.
 10. Rey RA, Grinspon RP, Gottlieb S, Pasqualini T, Knoblovits P, Aszpis S, et al. Male hypogonadism: An extended classification based on a developmental, endocrine physiology-based approach. *Andrology.* 2013;1(1):3-16.
 11. Zarotsky V, Huang M-Y, Carman W, Morgentaler A, Singhal PK, Coffin D, et al. Systematic literature review of the epidemiology of nongenetic forms of hypogonadism in adult males. *Journal of Hormones.* 2014;2014:1-17.
 12. Mulligan T, Frick MF, Zuraw QC, Stemhagen A, McWhirter C. Prevalence of hypogonadism in males aged at least 45 years: The HIM study. *International journal of clinical practice.* 2006;60(7):762-9.
 13. Sedlmeyer IL, Palmert MR. Delayed puberty: Analysis of a large case series from an academic center. *The Journal of clinical endocrinology and metabolism.* 2002;87(4):1613-20.
 14. Dye AM, Nelson GB, Diaz-Thomas A. Delayed Puberty. *Pediatric annals.* 2018;47(1):e16-e22.
 15. Chiang JM, Kaysen GA, Segal M, Chertow GM, Delgado C, Johansen KL. Low testosterone is associated with frailty, muscle wasting and physical dysfunction among men receiving hemodialysis: A longitudinal analysis. *Nephrology Dialysis Transplantation.* 2019;34(5):802-10.
 16. Cheung KK, Luk AO, So WY, Ma RC, Kong AP, Chow FC, et al. Testosterone level in men with type 2 diabetes mellitus and related metabolic effects: A review of current evidence. *Journal of diabetes investigation.* 2015;6(2):112-23.
 17. Bhasin S, Brito JP, Cunningham GR, Hayes FJ, Hodis HN, Matsumoto AM, et al. Testosterone therapy in men with hypogonadism: An endocrine society clinical practice guideline. *The Journal of clinical endocrinology and metabolism.* 2018;103(5):1715-44.
 18. Hohl A, Marques MOT, Coral MHC, Walz R. Evaluation of late-onset hypogonadism (andropause) treatment using three different formulations of injectable testosterone. *Arquivos Brasileiros de Endocrinologia & Metabologia.* 2009;53(8):989-95.
 19. Zhang GY, Gu YQ, Wang XH, Cui YG, Bremner WJ. Pharmacokinetic study of injectable testosterone undecanoate in hypogonadal men. *Journal of Andrology.* 1998;19(6):761-8.
 20. Kanakis GA, Nieschlag E. Klinefelter syndrome: More than hypogonadism. *Metabolism.* 2018;86:135-44.
 21. Swee DS, Quinton R, Maggi R. Recent advances in understanding and managing Kallmann syndrome. *Faculty Reviews.* 2021;10(37). <https://doi.org/10.12703/r/10-37>
 22. Topaloglu AK. Update on the genetics of idiopathic hypogonadotropic hypogonadism. *Journal of Clinical Research in Pediatric Endocrinology.* 2017;9(Suppl 2):113-22.
 23. Bianco SDC, Kaiser UB. The genetic and molecular basis of idiopathic hypogonadotropic hypogonadism. *Nature reviews Endocrinology.* 2009;5(10):569-76.
 24. Hayes F, Dwyer A, Pitteloud N. Hypogonadotropic hypogonadism (HH) and gonadotropin therapy (Updated 2013 Nov 25). In: Feingold KR, Anawalt B, Boyce A, et al., editors. *Endotext* [Internet]. South Dartmouth (MA): MDText.com, Inc.; 2000-. <https://www.ncbi.nlm.nih.gov/books/NBK279078/>
 25. Vogiatzi M, Tursi JP, Jaffe JS, Hobson S, Rogol AD. Testosterone use in adolescent males: Current practice and unmet needs. *Journal of the Endocrine Society.* 2020;5(1):bvaa161.
 26. Edelstein D, Basaria S. Testosterone undecanoate in the treatment of male hypogonadism. *Expert Opinion on Pharmacotherapy.* 2010;11(12):2095-106.
 27. Eisenberg ML, Jensen TK, Walters RC, Skakkebaek NE, Lipshultz LI. The relationship between anogenital distance and reproductive hormone levels in adult men. *The*

Journal of urology. 2012;187(2):594-8.

28. Liu Y, Fan L, Wang X, Gong C. Exploring the efficacy of testosterone undecanoate in male children with 5 α -reductase deficiency. *Pediatric Investigation*. 2021;5(4):249-54.
29. Skinner JW, Otzel DM, Bowser A, Nargi D, Agarwal S, Peterson MD, et al. Muscular responses to testosterone replacement vary by administration route: A systematic review and meta-analysis. *Journal Cachexia Sarcopenia Muscle*. 2018;9(3):465-81.
30. Dias JP, Melvin D, Simonsick EM, Carlson O, Shardell MD, Ferrucci L, et al. Effects of aromatase inhibition vs. testosterone in older men with low testosterone: randomized-controlled trial. *Andrology*. 2016;4(1):33-40.
31. Skinner JW, Otzel DM, Bowser A, Nargi D, Agarwal S, Peterson MD, et al. Muscular responses to testosterone replacement vary by administration route: A systematic review and meta-analysis. *J Cachexia Sarcopenia Muscle*. 2018;9(3):465-81.
32. Wood CL, Page J, Foggin J, Guglieri M, Straub V, Cheetham TD. The impact of testosterone therapy on quality of life in adolescents with Duchenne muscular dystrophy. *Neuromuscular disorders: NMD*. 2021;31(12):1259-65.