

Le Fort I and nasal fracture, primary reduction, and secondary revision saddle nose: A case report

Al Hafiz*¹, Wahyu Julianda¹

¹Department of Otorhinolaryngology-Head & Neck Surgery, Faculty of Medicine Universitas Andalas – M. Djamil General Hospital, Padang, Indonesia

Case Report

ABSTRACT

ARTICLE INFO

Keywords:

Le Fort I,
maxillofacial trauma,
nasal fracture,
saddle nose

*Corresponding author:

alhafiz@med.unand.ac.id

DOI: 10.20885/JKKI.Vol14.Iss2.art14

History:

Received: August 3, 2022

Accepted: July 30, 2023

Online: August 31, 2023

Copyright ©2023 Authors.

Maxillofacial trauma is a common clinical situation in emergency rooms. Lesions involving the maxillofacial complex pose a significant public health challenge, not only due to their costs but also because of the potential functional and aesthetic issues that patients may experience. While some fractures are more suitable for delayed treatment, others necessitate immediate attention, requiring intervention within 24 hours of the trauma occurrence. Different types of reduction and fixation exist depending on the patient's age, location, type of fracture, and the surgeon's preferences. We reported a case of a 20-year-old female patient diagnosed with Le Fort I bilateral fracture and closed nasal fracture followed by saddle nose. The patient was managed with open reduction internal fixation and closed reduction nasal bone. The saddle nose in the patient was managed four months later by augmentation rhinoplasty with rib cartilage and pearl fat graft. Proper management of Le Fort I fracture and nasal fracture accompanied with saddle nose by open reduction internal fixation and augmentation rhinoplasty with rib cartilage and pearl fat graft can restore occlusion and improve symmetrical, proportional facial aesthetics, which is the indicators of a successful holistic maxillofacial trauma management.

Trauma maksilofasial adalah situasi klinis umum di instalasi gawat darurat. Lesi yang melibatkan kompleks maksilofasial merupakan tantangan besar dalam kesehatan masyarakat, tidak hanya karena biayanya tetapi juga karena potensi masalah fungsional dan estetika yang dapat dialami pasien. Sementara beberapa fraktur lebih cocok untuk pengobatan yang ditunda, yang lain memerlukan perhatian segera, memerlukan intervensi dalam waktu 24 jam setelah terjadinya trauma. Berbagai jenis reduksi dan fiksasi ada tergantung pada usia pasien, lokasi, jenis fraktur, dan preferensi ahli bedah. Kami menyajikan sebuah kasus seorang pasien perempuan berusia 20 tahun dengan diagnosis patah bilateral Le Fort I dan fraktur nasal tertutup diikuti hidung pelana. Pasien dikelola dengan reduksi internal terbuka dan reduksi tertutup os nasale. Hidung pelana ditatalaksana empat bulan kemudian dengan rinoplasty augmentasi menggunakan kartilago kosta dan lemak. Manajemen yang tepat pada fraktur Le Fort I dan fraktur tulang hidung yang diikuti hidung pelana dengan fiksasi interna reduksi terbuka dan rinoplasti augmentasi menggunakan kartilago kosta dan lemak dapat memperbaiki keluhan oklusi dan memperbaiki kesimetrisan dan proporsi wajah yang merupakan indikator keberhasilan tatalaksana trauma maksilofasial secara holistik.

INTRODUCTION

Maxillofacial fracture, also called a midface fracture, is a break in the bones of the middle part of the face that form the upper jaw (maxilla). These bones include the maxilla, the zygoma (cheekbones), the lower rim and floor of the eye socket, and the nasal bones. Sometimes, maxillofacial fractures involve multiple facial

bones, also called complex fractures, and may partially or completely detach from the skull (Le Fort fractures). Le Fort fractures can be very severe and can be life-threatening.^{1,2}

The Le Fort classification is the most renowned categorisation within the realm of maxillary fractures classification.³ Initially elucidated by René Le Fort in 1901, Le Fort fractures delineate

distinct patterns of facial bone fractures that manifest as a result of blunt facial trauma, often linked to incidents like motorbike collisions, assaults, or falls.^{4,5}

Following this, post-traumatic nasal deformity emerges as one of the prevailing factors driving patients to seek consultations in medical practices.⁶ The saddle nose deformity specifically denotes the compromise in structural stability within the lower two-thirds of the nose, leading to both functional hindrance and aesthetic compromise.⁷

While certain fractures may be optimally managed with a deferred approach, others demand immediate attention and necessitate intervention within 24 hours of the traumatic incident. Varying methods of reduction and fixation are available, contingent upon factors such as the patient's age, fracture location and type, as well as the surgeon's preferences.⁸

CASE DESCRIPTION

We presented a case involving a 20-year-old female patient who was referred from the District Hospital to M. Djamil General Hospital with a suspected diagnosis of zygomatic fracture.

The day before admission, the patient had been riding a motorbike unaccompanied, wearing a helmet. Suddenly, the patient collided with a pedestrian who was crossing the street. As a result of the collision, the patient fell off the motorbike, making initial contact with the rearview mirror. Despite the impact, the patient remained conscious. Notably, congestion was observed at the accident site. The patient experienced facial swelling, particularly around both eyes. Importantly, there was no observed decline in vision, pain upon moving the eyeballs, or pain and difficulty when opening the mouth. Post-accident symptoms included headaches, with no reported instances of seizures. Following the incident, the patient was transported to the District Hospital, where a cranial computed tomography (CT) scan without contrast was performed. Subsequently, the patient was referred to M. Djamil General Hospital for further evaluation and treatment.

Upon physical examination, the patient's overall condition was assessed as moderately unwell, as indicated by a Glasgow Coma Scale (GCS) score of E4V5M6. The patient's blood pressure measured 112/68 mmHg, with a pulse rate of 84 beats per minute and a respiratory rate of 17 breaths per

minute. Notably, no oedema, deformities, or signs of battle at the ear were observed during the physical examination. Furthermore, an otoscopy examination yielded results within normal parameters.

During the examination of the external nose, noticeable findings included swelling and abrasion at the bridge of the nose. Assessing the nose for deformities, alignment, and crepitation proved challenging. On anterior rhinoscopy, the right and left nasal cavity was narrow, the inferior turbinate was oedema, the middle turbinate could not be evaluated, and there was excoriation at the anterior septum of the left nasal cavity.

Periorbital examination unveiled swelling and haematoma bilaterally, with no signs of bruising or restricted eyeball movement. The bilateral maxillary region displayed oedema and tenderness, and in the same area, there were signs of haematoma, crepitation, numbness, laceration, and abrasion (Figure 1B). Notably, there were no indications of malocclusion in the frontal, zygomatic, mandibular, or temporomandibular junction regions. In order to facilitate clinical assessment and guide future surgical planning, a series of photographs were captured from six different angles.

Cranial CT scan without contrast and three-dimensional (3D) reconstruction (Figure 2) showed a nasal bone fracture and fracture of both zygomaticomaxillary buttresses, the inferior portion of the piriform apertures, and both pterygoid plates. The patient was diagnosed with Le Fort I bilateral and closed nasal fractures. The patient was planned to perform open reduction and internal fixation (ORIF) and close reduction of nasal fracture under general anaesthesia after the oedema reduction.

Surgery was undertaken on the sixth day following admission. The patient's treatment encompassed an ORIF procedure for the Le Fort I fracture and a closed reduction of the nasal bones, all conducted under general anaesthesia.

Following the surgical intervention, the patient's post-operative regimen comprised intravenous administration of Ceftriaxone at a dosage of 1 g twice daily, Dexamethasone at 5 mg thrice daily, and ranitidine at 50 mg twice daily. Furthermore, oral Paracetamol was prescribed at 500 mg thrice daily. The patient's head was maintained at an elevated angle of 30-45°, and a

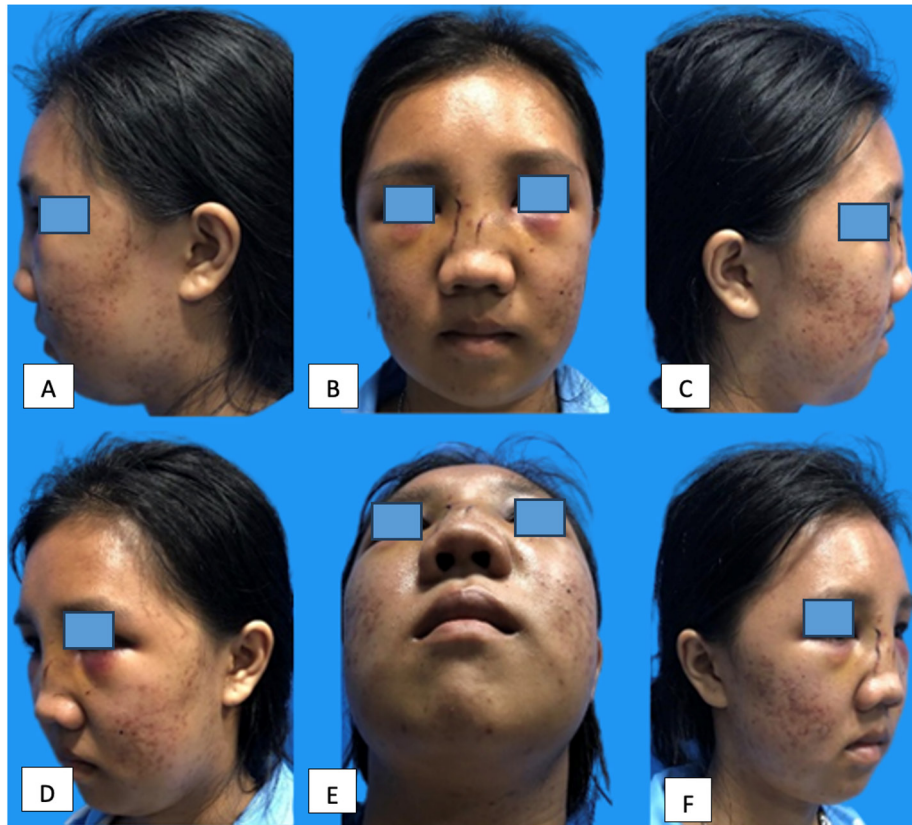

Figure 1. Post-accident picture of a patient

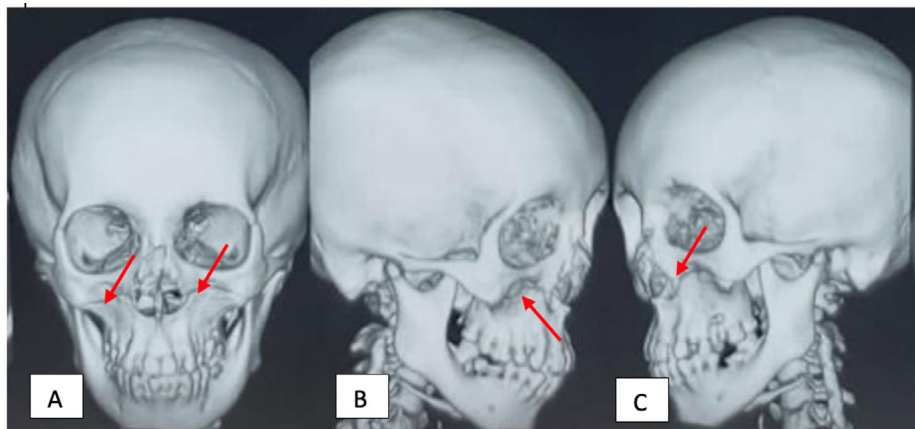


Figure 2. Three-dimensional CT scan facial view of a patient with a line of fracture (red arrow A-C)

liquid diet was provided during this period.

In the fourth month post-surgery, the patient returned to the ORL HNS outpatient clinic, expressing concern about a flattened nose. During the physical examination of the external nose, a noticeable deformity marked by a depression on the nasal dorsum was observed (Figure 3A). The patient's peak nasal inspiratory flow (PNIF) was measured at 110 litres per minute. The patient received a diagnosis of saddle nose deformity after a thorough evaluation. Consequently, a plan was formulated for an augmentation rhinoplasty

procedure involving rib cartilage and pearl fat graft use. This surgical intervention was executed under general anaesthesia.

The rhinoplasty procedure unfolded as follows: After extracting the necessary fat, an incision was meticulously extended until reaching the seventh rib. The rib graft was then carefully harvested and shaped to match the desired contour of the nasal dorsum.

The procedure commenced with a transcolumella incision, which was succeeded by inserting a rib cartilage graft onto the nasal

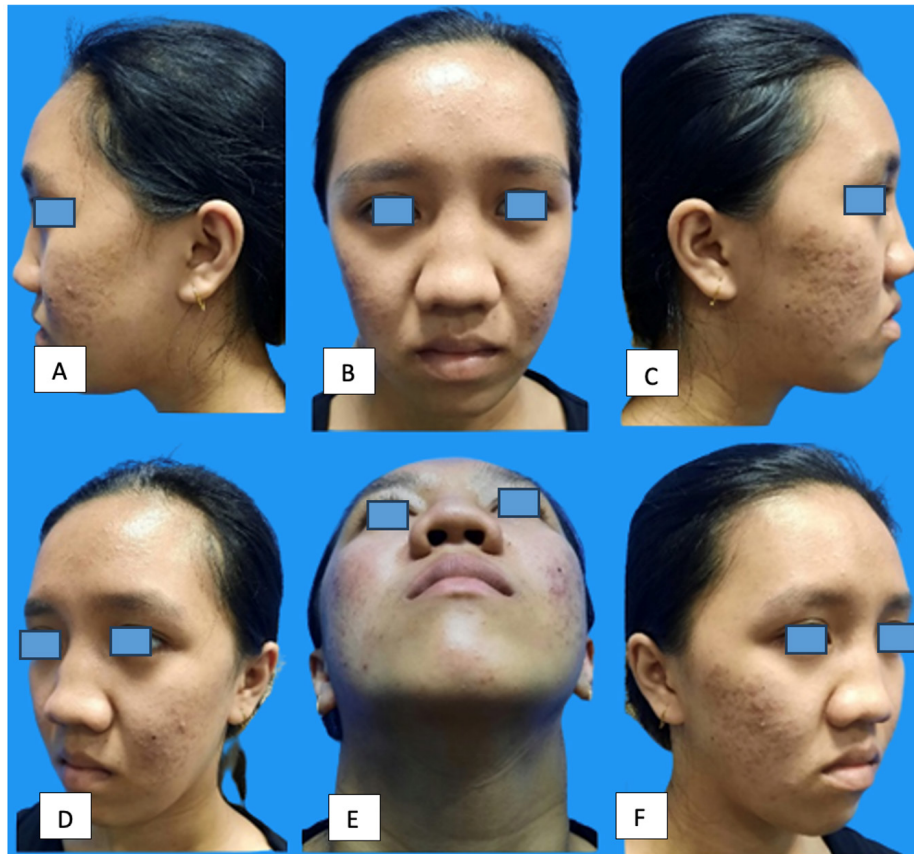

Figure 3. The patient's picture before the rhinoplasty procedure

dorsum, followed by suturing the columella and marginal incisions. Subsequently, subcutaneous fat was introduced to the nasal dorsum, and a plaster splint was applied to provide support.

One week post-surgery, the patient exhibited no indications of nasal congestion, bleeding, or pain from the nose. During the external nasal examination, no signs of oedema, hyperemia, tenderness, deformity, or incision site infection were observed (as illustrated in Figure 4B). The PNIF was measured at 110 litres per minute. Evaluation of the thorax region revealed satisfactory healing of the surgical wound.

DISCUSSION

We present a case report involving a 20-year-old female patient who was diagnosed with Bilateral Le Fort I fracture and closed nasal fracture. This initial diagnosis was followed by the development of saddle nose deformity, for which the patient underwent treatment consisting of ORIF, closed reduction of the nasal bone, and augmentation rhinoplasty using rib cartilage and pearl fat graft.

The patient exhibited several signs and symptoms, including infraorbital oedema,

haematoma, malocclusion, and a history of nosebleeds. It is worth noting that nosebleeds are a common complication following midfacial trauma, often arising due to disruption of the septal, nasal, or sinus mucosa or damage to the medial buttress. Furthermore, the patient had experienced a closed nasal fracture. According to statistical data, common physical examination findings in cases of nasal fracture presented at the emergency department encompassed tenderness (98%), nasal bleeding (69%), nasal deviation (63%), depression (58%), swelling (31%), and facial abrasion/laceration (18%).¹⁰

Signs indicative of orbital trauma, including periorbital ecchymosis, subconjunctival haematoma, and oedema, warrant careful consideration as they often signal the presence of an orbital fracture. The presence of "Raccoon eyes" or a "Battle" sign can further suggest anterior, middle, or posterior cranial base fractures. When assessing such cases, it is essential to evaluate various factors, including visual acuity, extraocular muscle function, the extent and presence of subconjunctival haemorrhage, the occurrence of diplopia, the presence of strabismus, as well as the

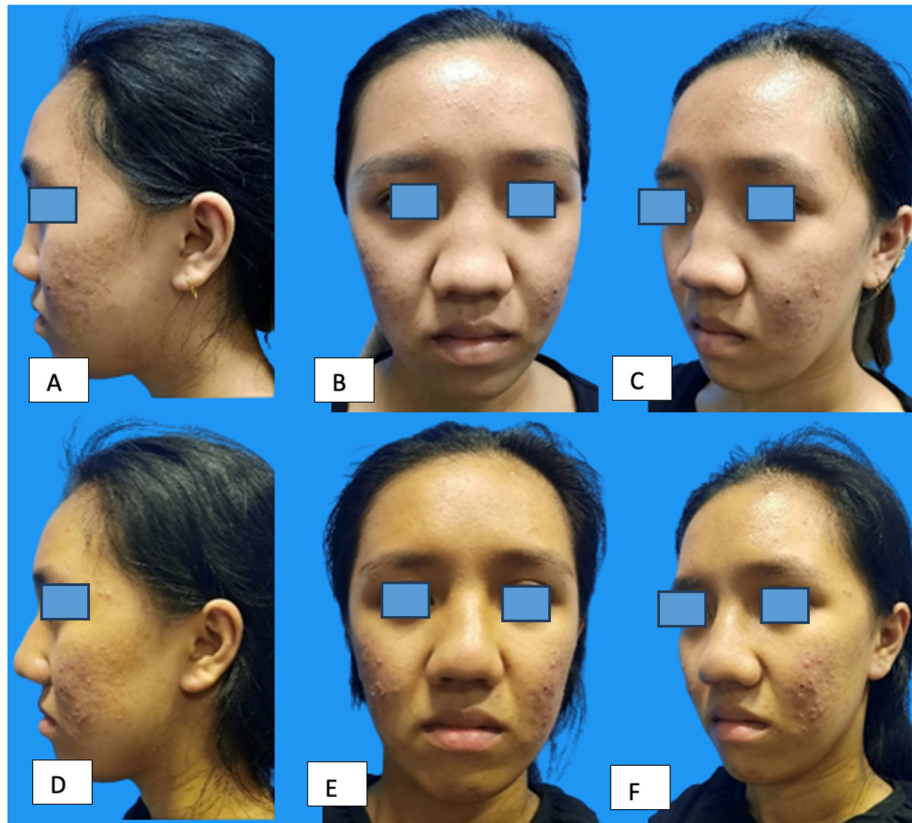


Figure 4. Before rhinoplasty (A-C) and after rhinoplasty (D-F) procedure

size, shape, and reactivity of the pupils to light.⁵

The objectives of treating Le Fort I fractures encompass the restoration of mid-facial height and projection and the re-establishment of occlusal relationships as they were before the trauma occurred. Furthermore, it is crucial to reinstate the structural support connecting the buttress areas and the maxillary alveolus to ensure correct soft tissue contouring.³ The fundamental tenets governing the management of Le Fort fractures entail infection control, reduction of fracture fragments, fixation, and immobilisation.⁹ For the majority of cases, irrespective of their specific type, open reduction with internal fixation is typically necessary when addressing Le Fort fractures.⁸

Treatment of nasal fractures, as with any facial fractures, is predicated on the severity of the fracture, with the primary objective of restoring pre-morbid form and function with the least invasive method available. Management options fall into four major categories from least to most invasive: observation, closed reduction, closed reduction with septoplasty, open reduction with or without internal stabilisation.¹²

In this case, a closed reduction of the nasal bone was conducted under general anaesthesia.

Instances, where a closed reduction of nasal bone fractures may not be recommended involve situations such as severely comminuted fractures affecting both the nasal bones and septum, open septal fractures, or fractures that are presented for treatment 2 to 3 weeks or more after the initial injury.¹³

The optimal timing for surgical treatment in nasal fractures is within the first few hours after injury (often elapsed by the time of patient presentation) or seven days to 10 days after the injury when acute oedema has begun to resolve. Closed reduction is best performed before fibrosis of fracture lines, typically within two weeks after injury but up to three weeks after it is described.¹²

On this patient, we found a saddle nose. The causes of saddle noses have changed over the years: infectious and toxic causes have become less frequent, while trauma and primary or secondary reduction rhinoplasties now represent the main causes of these deformities.¹⁴ Post-operative haematoma or septal abscess can lead to cartilage necrosis and a saddle nose.¹⁵ In this patient, the cause of the saddle nose is trauma itself.

The patient presents with a type III saddle nose, characterised by depression in both the

dorsum and lower third of the nose. The patient underwent rhinoplasty employing an external approach, where surgery included the use of grafts to achieve the desired aesthetic and functional outcomes.¹⁵ In this case, we performed rhinoplasty four months after the initial procedure. In the acute setting, aside from closed nasal reduction and laceration repair, most practitioners avoid performing definitive open septorhinoplasty requiring extensive dissection and cartilage grafting. The trend is to perform conservative procedures acutely and wait 3 to 6 months before considering a definitive open septorhinoplasty once all the soft tissue trauma and cartilage contracture forces have stabilised to reflect the long-term appearance and nasal airflow more accurately. The reasoning for initial conservative, less invasive treatment in the acute setting is that several variables can influence the final, long-term outcomes both cosmetically and functionally.^{16,17}

In this case, autograft material was employed. The use of autografts is considered superior to synthetic materials, which carry the potential for complications such as extrusion, migration, foreign body reactions, or chronic infection.¹⁸ Autografts remain the preferred option for saddle nose reconstruction.^{19,20}

CONCLUSION

Effective management of a Le Fort I fracture, combined with saddle nose deformity, involves employing open reduction internal fixation alongside augmentation rhinoplasty utilising rib cartilage and pearl fat graft. This comprehensive approach reestablishes proper occlusion and enhances facial aesthetics in terms of symmetry and proportion. These outcomes serve as benchmarks for the success of a comprehensive approach to managing maxillofacial trauma.

CONFLICT OF INTEREST

The authors declare that they have no competing interests. The patient has agreed to carry out scientific publications as a learning tool.

ACKNOWLEDGEMENT

None

REFERENCES

1. Lanas G, Paredes F, Vallejo K, Lanas A, Zindel-Deboni MC. Epidemiology and compli-

2. cations of facial fractures: a 5-year retrospective study. *Rev Fac Odontol Univ Antioq.* 2019;30(2):191–201.
2. Lee UK, Rojhani A, Herford AS, Thakker JS. Immediate versus delayed treatment of mandibular fractures: A stratified analysis of complications. *J Oral Maxillofac Surg.* 2016;74(6):1186–96.
3. Kim HS, Kim SE, Lee HT. Management of Le Fort I fracture. *Arch Craniofacial Surg.* 2017;18(1):5–8.
4. Phillips BJ, Turco, Lauren M. Le Fort Fractures: A Collective Review. *Bull Emerg Trauma.* 2017;5(4):221–30.
5. Brady CM, Odonno LT, Urata M. Le Fort Fractures. In: Bagheri, Shahrokh C, Rodriguez, Eduardo D, Manson, Paul N, editors. *Facial Trauma Surgery: From Primary Repair to Reconstruction.* New York: Elsevier Inc.; 2020. p. 147–67.
6. Chua DYK, Park SS. Post-traumatic Nasal Deformities: Correcting the Crooked and Saddle Nose. *Facial Plast Surg.* 2015;31(3):259–69.
7. Ms REW, Gliklich RE, Fuller JC. Review of literature of saddle nose deformity reconstruction and presentation of vomer onlay graft. *Laryngoscope Investig Otolaryngol.* 2020;5:1039–43.
8. Chouinard, Anne F, Troulis MJ, Lahey ET. The Acute Management of Facial Fractures. *Curr Trauma Reports.* 2016;2(2):55–65.
9. Adiantoro S, Kasim A, Faturrahman F. Management of le fort ii fracture accompanied with blowout fracture of orbital base (case report. *J Dentomaxillofacial Sci.* 2017;2(2):143–6.
10. Chou C, Chen CW, Wu YC, Chen KK, Lee SS. Refinement treatment of nasal bone fracture: A 6-year study of 329 patients. *Asian J Surg.* 2015;38(4):191–8.
11. Nam AJ, Davidson EH, Manson PN. Assessment of the Patient With Traumatic Facial Injury. In: Dorafshar, Amir H, Rodriguez, Eduardo D, Manson, Paul N, editors. *Facial Trauma Surgery From Primary Repair to Reconstruction.* 1st Editio. New Delhi: Elsevier; 2020. p:1–15.
12. Lu GN, Humphrey CD, Kriet JD. Correction of Nasal Fractures. *Facial Plast Surg Clin North Am.* 2017;25(4):537–46.
13. Sirhan A, Patel, Bhupendra C. *Nasal Fracture Reduction.* StatPearls Publishing; 2021.
14. Durbec M, Disant F. Saddle nose: Classi-

- fication and therapeutic management. *Eur Ann Otorhinolaryngol Head Neck Dis.* 2014;131(2):99-106.
15. Chen, Yung Y, Jang, Yong J. Refinements in Saddle Nose Reconstruction. *Facial Plast Surg.* 2018;34:263-372.
 16. Wang W, Lee T, Kohlert S, Kadakia S, Ducic Y. Nasal Fractures: The Role of Primary Reduction and Secondary Revision. *Facial Plast Surg.* 2019;35(6):590-601.
 17. Malhotra M, Varshney S, Joshi P, Gupta S, Malhotra R, Singh V. A Modified Technique of Rhinoplasty using Cortical Bone Graft to correct Saddle Nose Deformity with Loss of Septal Cartilage. *Exp Rhinol Otolaryngol.* 2018;2(1):1-5.
 18. Guisantes E. The Chrysalis Graft: Combination of Diced-Cartilage-Fascia Grafts and PRP in Augmentation Rhinoplasty. *Int J Transplant Plast Surg.* 2019;3(1):1-11.
 19. Robitschek J, Hilger P. The Saddle Deformity: Camouflage and Reconstruction. *Facial Plast Surg Clin North Am.* 2017;25(2):239-50.
 20. Delacure M. Reconstructive Head and Neck Surgery. In: KJ Lee *Essential Otolaryngology Head & Neck Surgery.* Ninth Edition, McGrawHill, 2008. p:40-55