

## Clove flower extracts (*Syzygium aromaticum*) increased incision wound epithelization, platelet count, and TGF- $\beta$ levels in methicillin-resistant *Staphylococcus aureus*-infected rats

Suryo Wibowo<sup>\*1</sup>, Endang Sri Lestari<sup>2</sup>, Muhammad Thohar Arifin<sup>3</sup>, Yan Wisnu Prajoko<sup>4</sup>, Neni Susilaningsih<sup>5</sup>

<sup>1</sup>Magister of Biomedicine, Faculty of Medicine, Diponegoro University, Semarang, Indonesia

<sup>2</sup>Department of Microbiology, Faculty of Medicine, Diponegoro University, Semarang, Indonesia

<sup>3</sup>Department of Neurosurgery, Faculty of Medicine, Diponegoro University, Semarang, Indonesia

<sup>4</sup>Department of Oncology Surgery, Faculty of Medicine, Diponegoro University, Semarang, Indonesia

<sup>5</sup>Department of Histology, Faculty of Medicine, Diponegoro University, Semarang, Indonesia

Original Article

### ABSTRACT

#### ARTICLE INFO

##### Keywords:

MRSA infection,  
Wound healing,  
Clove flower,  
Platelet count,  
TGF- $\beta$ ,  
Epithelization

##### \*Corresponding author:

soerwib@gmail.com

DOI: 10.20885/JKKI.Vol14.Iss3.art4

##### History:

Received: March 27, 2023

Accepted: December 6, 2023

Online: December 30, 2023

Copyright ©2023 Authors.

**Background:** The wound healing process consists of three phases, namely inflammation, proliferation, and remodeling. Many cells and mediators are involved in this process, including platelets and transforming growth factor- $\beta$  (TGF- $\beta$ ). Methicillin-resistant *Staphylococcus aureus* (MRSA) is a bacterial strain resistant to beta-lactam antibiotics. Clove flower (*Syzygium aromaticum*) is an herb with properties to promote wound healing

**Objective:** To determine the effect of clove flower extract on increasing epithelialization of incision wounds, platelet counts, and TGF- $\beta$  levels in mice infected with MRSA

**Methods:** A randomized experimental study on 30 male wistar rats (*Rattus norvegicus*) infected with MRSA. All rats were randomly divided into six groups; healthy control, positive control induced by MRSA and Vancomycin 9 mg/200 gram body weight (gbw), negative control MRSA with normal saline, and administration of clove flower extract (CFE) 25 mg/200 gbw, CFE 50 mg/200 gbw, and CFE 100 mg/200 gbw. Examination of the sectioned wound epithelium was performed histologically using Hematoxylin-Eosin (HE), while platelet count and TGF- $\beta$  levels were measured using an ELISA RAB0479 kit simultaneously on the 21<sup>st</sup> day.

**Results:** Histological examination of rats treated with CFE 100 mg/200 gbw and uninfected rats showed complete epithelization. Platelet counts and TGF- $\beta$  levels were significantly higher in rats administered CFE 100 mg/200 gbw ( $p < 0.001$ ) compared to the other five groups.

**Conclusion:** Administering CFE increased incision wound epithelialization, platelet count, and TGF- $\beta$  levels in MRSA-infected rats.

**Latar Belakang:** Proses penyembuhan luka terdiri dari 3 fase, yakni inflamasi, proliferasi, dan remodeling. Banyak sel dan mediator terlibat dalam proses ini, termasuk trombosit dan TGF- $\beta$ . Bakteri MRSA merupakan sebuah strain bakteri yang resisten terhadap antibiotik beta-laktam. Cengkeh (*Syzygium aromaticum*) merupakan sebuah tanaman herbal yang memiliki kemampuan untuk mempromosikan penyembuhan luka.

**Tujuan:** Mengetahui pengaruh ekstrak bunga cengkeh terhadap peningkatan epitelisasi luka insisi, jumlah trombosit, dan kadar TGF- $\beta$  pada mencit yang terinfeksi Methicillin-Resistant *Staphylococcus aureus*

**Metode:** Penelitian eksperimental acak dilakukan pada 30 ekor mencit Wistar (*Rattus norvegicus*) jantan yang secara acak dibagi menjadi 6 kelompok; kontrol sehat, kontrol negatif yang diinduksi MRSA dan diberikan larutan normal saline, kontrol positif yang diinduksi MRSA dan diberikan antibiotik Vancomycin 9 mg/200 gram berat badan (gbb), dan 3 kelompok perlakuan yang diinduksi MRSA dan pemberian ekstrak bunga cengkeh dengan dosis 25 mg/200gbb, dosis 50 mg/200gbb, dan dosis 100 mg/200gbb. Pengamatan terhadap epitelisasi luka dilakukan secara histologis dengan pewarnaan Hematoksin-Eosin, sementara perhitungan jumlah trombosit dan kadar TGF- $\beta$  diukur dengan ELISA kit RAB0479 secara bersamaan pada hari ke-21.

**Hasil:** Pemeriksaan histologi pada mencit yang diberikan ekstrak bunga cengkeh 100 mg/200 gbb dan mencit yang tidak terinfeksi menunjukkan epitelisasi sempurna. Jumlah trombosit dan kadar TGF- $\beta$  secara signifikan lebih tinggi pada mencit yang diberikan ekstrak bunga cengkeh 100 mg/200 gbb ( $p < 0.001$ ) dibandingkan dengan lima kelompok lainnya

**Kesimpulan:** Pemberian ekstrak bunga cengkeh meningkatkan epitelisasi luka, jumlah trombosit, dan kadar TGF- $\beta$  pada mencit yang terinfeksi MRSA

## INTRODUCTION

A wound is a condition in which the integrity of biological tissue is compromised. The wound healing process includes the phases of inflammation, proliferation, and remodeling, involving various factors and the role of many cells and their mediators.<sup>1</sup> Platelets are one of the components involved in each phase of wound healing. During periods of hemostasis and inflammation, platelet aggregation forms a clot that can stop bleeding and help recruit immune cells. During the proliferative phase, platelets release angiogenesis and growth factors such as TGF- $\beta$  and platelet-derived growth factor (PDGF), which play a role in the granulation tissue and epithelium to fill the wound defect.<sup>2</sup> Platelets also secrete matrix metalloproteinases (MMPs) and release hydrolases from their lysosomes during a remodeling step involved in tissue preparation and repair.

*Staphylococcus aureus* is a bacteria that colonizes the skin in 30% of healthy individuals.<sup>3</sup> The MRSA is a strain that is resistant to beta-lactam antibiotics and is the most common cause of opportunistic and nosocomial wound infections.<sup>4</sup> Colonization of wounds with superficial MRSA can delay wound healing. The MRSA is associated with longer hospital stays, patient morbidity, and mortality.<sup>5</sup> Infection of MRSA is a global health-threatening bacteria in healthcare settings, which is resistant to antibiotics, making it difficult to treat and making it necessary to search for alternative treatment.<sup>6</sup>

Clove flower (*Syzygium aromaticum*) is a natural ingredient widely used in herbal medicine. The clove flower is a plant native to Indonesia that is abundant, making it easily available at a relatively low cost, and has been shown in vitro to have anti-bacterial activity.<sup>7,8</sup> Most clove flower extracts contain eugenol, which is derived from

cloves' active compounds, such as polyphenols, flavonoids, saponins, alkaloids, steroids, triterpenoids, and tannins.<sup>9</sup> A study by Rahmawati et al. demonstrated that clove flower extract can inhibit and kill the bacterium *S. aureus*.<sup>8</sup> Therefore, this study aimed to investigate the effects of clove extract on wound healing in MRSA-infected rats, as assessed by wound epithelium, platelet count, and TGF- $\beta$  levels.

## METHODS

### Preparation with clove flower extract

The clove flower was obtained directly from clove farmers in the Temanggung region who had undergone a selection process to select cloves that possess a fragrant aroma. Subsequently, the clove blossoms are crushed into granules using a pounding tool and weighed as per the required quantity. One hundred grams of clove flower powder was soaked in ethanol to a volume of 1,000 ml, stirred for 24 hours until settled, and placed in a spray bottle. The evaporating flask is placed on the evaporator and fills the water bath with water to the brim. All instruments, including the rotary evaporator and bath heater (set at 80-90°C) are installed and connected. After the ethanol solution has already separated from the active substance in the evaporating flask, this should be left to stand until the stream of ethanol no longer drips into the receiving flask ( $\pm 1.5$  to 2 hours for a flask). The result is about a quarter of the original amount of dried clove flowers. The extraction results are stored in plastic bottles in the fridge or freezer.

### Population and sampling

Thirty male Wistar rats (*Rattus norvegicus*) were calculated using formula =  $(Z2 \times \text{Standard Deviation (SD)} \times (1 - \text{SD}) / \text{Confidence Interval (CI)}^2)$ , aged between 2-3 months and weighed 200 grams, were used as experimental models.

### Data collection

All rats that met the inclusion criteria were then adapted and given food and water ad libitum for ten days. Before the incision, an injection of ketamine 40-100 mg/kgbw and xylazine 5-13 mg/kgbw was given for anesthesia. A 2-cm incision was made and deepened until reached the subcutaneous layer, parallel to the vertebrae on the rat's back. Thirty rats were randomized

into six groups, each consisting of five rats that had previously been wounded: group C1 received standard wound care only with normal saline; Group C2 was induced by MRSA infection and given normal saline; Group C3 was induced by MRSA infection and received vancomycin (9 mg/200 g); The T1 group was induced by MRSA infection and received 25 mg/200 gbw of CFE; Group T2 was induced by MRSA infection and received 50 mg/200 gbw CFE; and the T3 group was induced by MRSA infection and received 100 mg/200 gbw of CFE. The MRSA was artificially induced by inoculating 30  $\mu$ L suspension of 10<sup>5</sup> colony-forming units (CFU) of MRSA obtained from the Microbiology Laboratory of Diponegoro University Faculty of Medicine that were put inside the test tube accordingly on the wounds. For each treatment with CFE, a single dose was administered ad libitum per day for ten days. On day 21, all rats were euthanized with a lethal dose of ketamine 40-100 mg/kgbw. After the samples were taken for analysis, the rats were cremated to minimize the risk of transmitting the infection. The skin tissue was obtained from the back of the treated rats. Blood samples from the rat's orbital sinus were collected in the range of 2-5 cc.

### Outcome assessment

The incised skin was removed and fixed with 10% neutral buffered formalin for three days. The sample was then dehydrated in ethanol and cleared with xylene before being embedded in paraffin. Sections of 2-5  $\mu$ m were deparaffinized with xylene and stained with HE. The samples were examined using light microscopy by a pathologist unfamiliar with study protocols. Wound epithelization was defined as covering a denuded epithelial surface and refers to the development of a new epidermis. Wound sample was sectioned into three microscope fields of view, and the widest gap between the new epidermis that was formed in each of the wound edges in each section was measured. The mean of the three sections was addressed in  $\mu$ m. Platelet count was measured from blood smears that were examined in 10 fields or more under oil immersion (x100), and the average number of platelets was determined by dividing the total platelets by the number of fields viewed. TGF- $\beta$  levels were determined using the ELISA RAB0479 kit.

### Statistical analysis

Distribution of the incision wound epithelial data, platelet count, and TGF- $\beta$  levels were analyzed with the Shapiro-Wilk test using the SPSS 10.0 statistical software. Statistical parametric analysis was performed for normally distributed data. Otherwise, a Kruskal-Wallis test followed by a Mann-Whitney test was performed to determine differences between groups. A difference is considered significant if  $p < 0.05$  with a 95% confidence interval.

### Ethics

The experiments were performed according to the institutional guidelines, and the protocol was approved by the Ethics Committee for Health Research of the Universitas Diponegoro School of Medicine (protocol number: 07/EC/H/FK-UNDIP/1/2023)

## RESULTS

### Incision wound epithelization

Wound epithelium assessment after the incision was performed based on the distance between the wound edges (Figure 1). The comparison among the groups is presented in Table 1. The difference in incisional epithelium between the groups was analyzed by One-Way ANOVA. A significant difference was found in wound epithelization between the study groups. Post-hoc analysis result, presented in Table 1, showed no difference between the C1 and C2 groups. The greatest wound edge gap was in group C2 (9,509.41  $\pm$  1,802.86  $\mu$ m), while the narrowest gap was in group T3 (142.21  $\pm$  29.03  $\mu$ m).

### Platelet count

Platelet counts were measured from a blood sample taken on day 21 of the study. The comparison among the group is presented in Table 3. The difference in platelet count between the groups was analyzed using the Kruskal-Wallis test. There was a significant difference in platelet counts between the study groups. Mann-Whitney analysis, presented in Table 2, revealed that T3 group had the highest platelet count (1,211.87  $\pm$  4.76  $\times 10^3/\mu$ l), while C2 group had the lowest (369.29  $\pm$  45.28  $\times 10^3/\mu$ l).

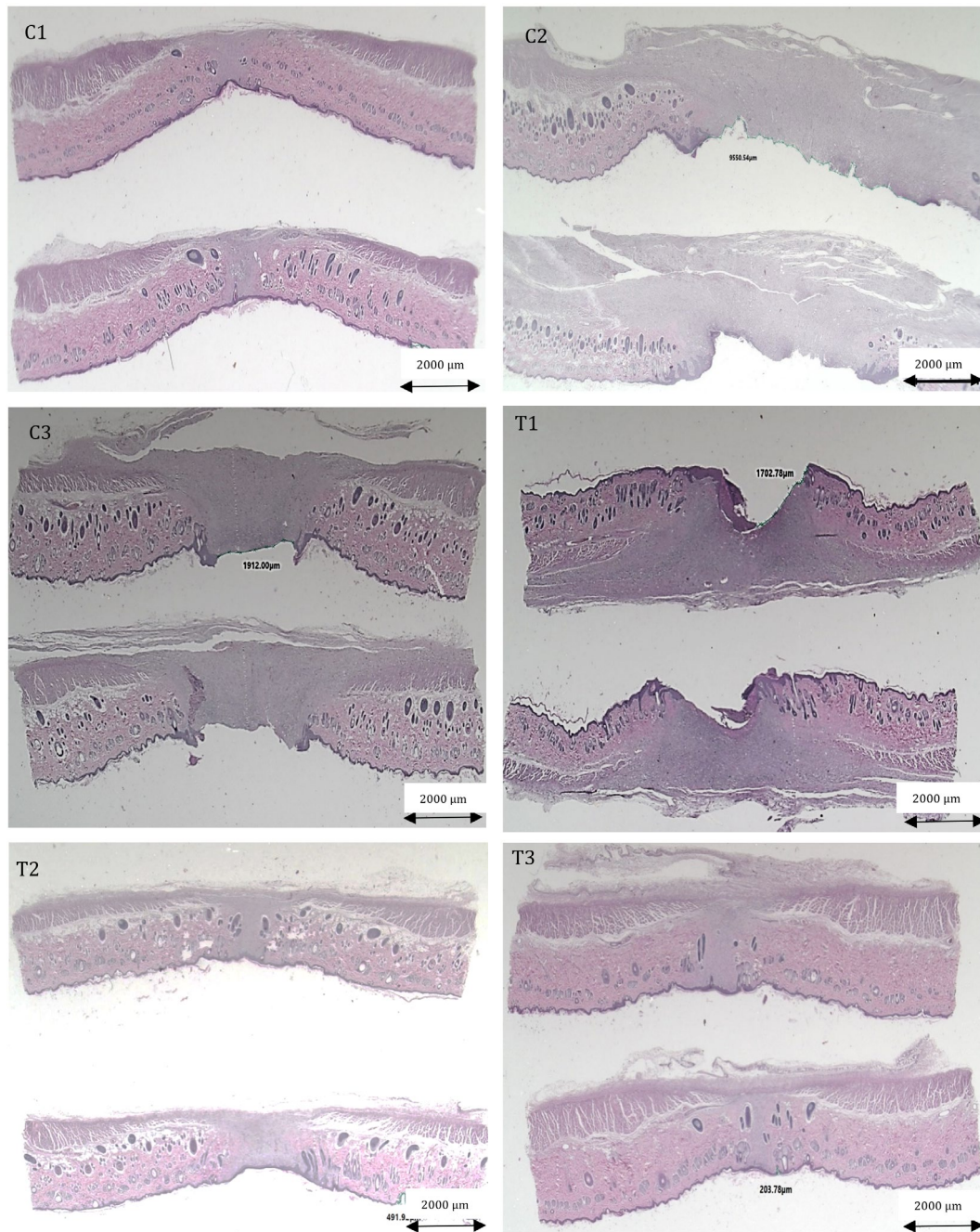


Figure 1. Histopathologic examination of incision wound epithelization of each group. C1: healthy rats with incision only; C2: MRSA-infected rats with incision wound and saline; C3: MRSA-infected rats with incision wound and vancomycin; T1: MRSA-infected rats with incision wound and 25 mg/200 gbw clove flower extract (CFE); T2: MRSA-infected rats with incision wound and 50 mg/200 gbw CFE; and T3: MRSA-infected rats with incision wound and 100 mg/200 gbw CFE. Hematoxylin eosin stain, 100X magnification

### The TGF- $\beta$ levels

Levels of TGF- $\beta$  were also measured in a blood sample taken on day 21 of the study. The comparison among the groups was presented in Table 5. The difference in TGF- $\beta$  levels between each group was analyzed by one-way ANOVA and a significant difference was found between the study groups. Post-Hoc analysis, presented in

Table 3, showed that the highest TGF- $\beta$  level was in the T3 group ( $21.03 \pm 0.48$  ng/ml), while the lowest TGF- $\beta$  level was in C2 ( $7.01 \pm 0.23$  ng/ml).

### DISCUSSION

This study investigated the effect of CFE on the wound healing process in MRSA-infected rats as assessed by wound gaps, platelet counts, and

Table 1. Wound gaps among the study groups

Groups	Mean ± SD (µm)	p <sup>£</sup>	Post-hoc analysis	p
C1	6,310.08 ± 266.78		C2	0.086
			C3	<0.001*
			T1	<0.001*
			T2	<0.001*
C2	9,509.41 ± 1802.86	<0.001*	T3	<0.001*
			C3	0.005*
			T1	0.003*
			T2	0.002*
C3	2,545.92 ± 118.99	<0.001*	T3	0.002*
			T1	0.02
			T2	<0.001*
T1	1,519.80 ± 219.69	<0.001*	T3	<0.001*
			T2	0.003*
			T3	0.001*
T2	550.37 ± 22.54		T3	<0.001*
T3	142.21 ± 29.03			

Description: <sup>£</sup>One-Way ANOVA; C1: healthy rats with an incision only; C2: MRSA-infected rats with incision wound and saline; C3: MRSA-infected rats with incision wound and vancomycin; T1: MRSA-infected rats with incision wound and 25 mg/200 gbw clove flower extract; T2: MRSA-infected rats with incision wound and 50 mg/200 gbw clove flower extract; and T3: MRSA-infected rats with incision wound and 100 mg/200 gbw clove flower extract. \* Significant (p<0.05)

Table 2. Platelet count and Kruskal-Wills analysis among the study groups

Groups	Mean ± SD (x10 <sup>3</sup> /µm)	p <sup>£</sup>	Post-hoc analysis	p
C1	989.40 ± 8.37		C2	0.008*
			C3	0.008*
			T1	<0.001*
			T2	0.008*
			T3	0.009*
C2	369.29 ± 45.28	<0.001*	C3	0.008*
			T1	0.008*
			T2	<0.001*
			T3	0.008*
C3	757.39 ± 4.50	<0.001*	T1	0.008*
			T2	0.008*
			T3	0.008*
T1	1,029.52 ± 18.82	<0.001*	T2	0.008*
			T3	0.008*
T2	1,105.01 ± 16.15		T3	0.008*
T3	1,211.87 ± 4.76			

Description: <sup>£</sup>Kruskal-Wallis; C1: healthy rats with incision only; C2: MRSA-infected rats with incision wound and saline; C3: MRSA-infected rats with incision wound and vancomycin; T1: MRSA-infected rats with incision wound and 25 mg/200 gbw clove flower extract; T2: MRSA-infected rats with incision wound and 50 mg/200 gbw clove flower extract; and T3: MRSA-infected rats with incision wound and 100 mg/200gbw clove flower extract.\* Significant (p<0.05)

Table 3. TGF- $\beta$  levels and Mann-Whitney analysis among the study groups

Groups	Mean $\pm$ SD (ng/mL)	p <sup>f</sup>	Mann-Whitney	p
C1	9.00 $\pm$ 0.21		C2	<0,001*
			C3	0,023*
			T1	<0,001*
			T2	<0,001*
			T3	<0,001*
C2	7.01 $\pm$ 0.23	<0,001*	C3	0,002*
			T1	<0,001*
			T2	<0,001*
C3	8.23 $\pm$ 0.32	<0,001*	T3	<0,001*
			T1	<0,001*
			T2	<0,001*
T1	10.92 $\pm$ 0.32	<0,001*	T3	<0,001*
			T2	0,001*
			T3	<0,001*
T2	12.76 $\pm$ 0.42	<0,001*	T3	<0,001*
			T3	<0,001*
			T3	<0,001*
T3	21.03 $\pm$ 0.48			

Description: <sup>f</sup>Kruskal-Wallis; C1: healthy rats with incision only; C2: MRSA-infected rats with incision wound and saline; C3: MRSA-infected rats with incision wound and vancomycin; T1: MRSA-infected rats with incision wound and 25 mg/200 gbw clove flower extract; T2: MRSA-infected rats with incision wound and 50 mg/200 gbw clove flower extract; and T3: MRSA-infected rats with incision wound and 100 mg/200gbw clove flower extract.\* Significant ( $p < 0.05$ )

TGF- $\beta$  levels. The impairment of wound healing is caused by MRSA's secretion of virulence factors, resulting in elevated bacterial colony growth and the development of antimicrobial resistance within skin wounds.<sup>10</sup> Infection by this strain impairs thrombocyte adhesion and aggregation healing while lowering TGF- $\beta$  as one of the cytokines involved in wound healing.<sup>11</sup> We induced MRSA-infected wounds by inoculating suspension containing 10<sup>5</sup> CFU of MRSA on the wounds as previously described by Dai et al.<sup>12</sup>

The administration of CFE at a dose of 100 mg/200 gbw resulted in better epithelization of the incision wound. This finding aligns with prior research demonstrating that CFE's anti-bacterial properties are attributable to its phytochemical composition, including eugenol, which plays a significant role in its antimicrobial characteristics. Pratiwi reported that CFE use resulted in a faster epithelization process, wound closure, and an inflammatory phase.<sup>13</sup> The CFE contains lots of bioactive components with diverse benefits. Carvalho et al. showed that flavonoids, one of the bioactive compounds found in clove flowers,

have an anti-inflammatory effect by inhibiting and modulating pro-inflammatory molecule gene expression.<sup>14</sup> Other component, such as saponin, has also been reported to elicit anti-bacterial, anti-tumor, antioxidant, and anti-inflammatory effects, thus highlighting the potential benefit of using this substance.<sup>15</sup>

Platelets are small cell nuclei derived from the hematopoietic pathway of megakaryocytes and play a crucial role in all four stages of wound healing.<sup>16</sup> The MRSA-infected rats with incision wound and normal saline has the lowest platelet count, indicating that infection by MRSA impairs healing. The MRSA is known to have high hemolytic activity, which carries a high risk of thrombocytopenia.<sup>17</sup> The virulence factor of MRSA is associated with an increased number of bacteria entering host cells.<sup>18</sup> The number of platelets in the 100 mg/200 gbw group was significantly higher than in the other groups, suggesting that the administration of clove flower extract has a beneficial effect on wound healing. This result is consistent with a study by Arora et al., who found a significant increase in platelet counts 24 hours

and 14 days after administration of clove flower extract by 9% and 23%, respectively.<sup>19</sup>

The TGF- $\beta$  is a growth factor that has a role in inflammation, stimulation of angiogenesis, fibroblast proliferation, synthesis and deposition of collagen, and remodeling of new extracellular matrix.<sup>20</sup> This study showed the highest levels of TGF- $\beta$  in the 100 mg/200 gbw group and the lowest in the normal saline group. These results indicate that MRSA infection impairs wound healing, consistent with a narrative review by Simonetti et al., which states that bacterial infection, more often polymicrobial and multidrug-resistant, delays the healing of these wounds.<sup>21</sup> Clove flower extract administration has shown a positive effect on the healing process, especially at a dose of 100 mg/200 gbw, characterized by high levels of TGF- $\beta$ . These results agree with a study by Ali et al., which showed that the administration of CFE affected wound healing in rats with type 1 diabetes. The increase in wound healing markers, such as TGF- $\beta$ , Coli1, MMP-9, proliferating cell nuclear antigen (PCNA), and fibronectin, were indications of wound healing in this study.<sup>22</sup> The TGF- $\beta$  is known to have pleiotropic effects on wound healing through the regulation of cell proliferation, differentiation, extracellular matrix production, and immune response modulation. An increased level of TGF- $\beta$  could indicate better wound healing, whereas impaired TGF- $\beta$  signaling has shown to delay wound healing.<sup>23</sup>

This study has several limitations. In this study, measurement was on day 21 after ten days of treatment. Theoretically, the epithelial healing process begins on day 3 when an epithelial lining covers the wound bed. In 24 hours after injury, keratinocytes migrate laterally and regenerate the basement membrane. Once keratinocytes have formed, they stop migrating and multiply until they peak on day 4.

## CONCLUSION

This study has shown that administration of clove flower 100 mg/200 g dose extract increased wound epithelization, platelet count, and TGF- $\beta$  levels in MRSA-infected rats. Therefore, further studies can regularly compare the effect of extract administration on wound healing components

## CONFLICT OF INTEREST

The authors declare that they have no potential

conflict of interest or personal relationships that could have appeared to influence the work reported in this paper.

## ACKNOWLEDGEMENT

This work was supported by the Department of Biomedical Science Postgraduate Program, Faculty of Medicine, Diponegoro University. We thank Department of Biological Sciences Gadjah Mada University for providing the facility needed to conduct the research.

## AUTHOR CONTRIBUTION

Each author contributed greatly towards this study, SW made significant, original, and insightful intellectual contributions, participate in the conception and planning of the study, generate data through performing experiments, conducting literature reviews, and organizing surveys and interviews analyze the results through statistical analysis and by generating graphs, tables, and illustrations, write and edit the manuscript, help with queries and revisions after submission; ESL helped in preparing a submission-ready manuscript with the necessary files; MTA put together a submission package and stay in close-contact with the publisher; YWP ensured authorship details are correct have all authors-review and approve the final version, and NS managed open-access details, deal with the payment and invoicing.

## LIST OF ABBREVIATION

TGF- $\beta$ : Transforming Growth Factor- $\beta$ ; MRSA: Methicillin-Resistant *Staphylococcus aureus*; PDGF: Platelet-derived growth factor; MMP: Matrix Metalloproteinases; PCNA: Proliferating Cell Nuclear Antigen, CFE: Clove Flower Extract

## REFERENCES

1. Soliman AM, Barreda DR. Acute inflammation in tissue healing. *Int J Mol Sci.* 2022;24(1).
2. Locatelli L, Colciago A, Castiglioni S, Maier JA. Platelets in wound healing: What happens in space? *Front Bioeng Biotechnol.* 2021;9:716184.
3. Howden BP, Giulieri SG, Wong Fok Lung T, Baines SL, Sharkey LK, Lee JYH, et al. *Staphylococcus aureus* host interactions and adaptation. *Nat Rev Microbiol.* 2023;21(6):380–95.

4. Masimen MAA, Harun NA, Maulidiani M, Ismail WIW. Overcoming methicillin-resistance *Staphylococcus aureus* (MRSA) using antimicrobial peptides-silver nanoparticles. *Antibiotics* (Basel). 2022 ;11(7).
5. Kourtis A, Hatfield K, Baggs J, Mu Y, See I, Epton E, et al. Morbidity and mortality weekly report vital signs: Epidemiology and recent trends in methicillin-resistant and in methicillin-susceptible *Staphylococcus aureus* bloodstream infections - United States. *MMWR Morb Mortal Wkly Rep*. 2019;68(9):214–9.
6. Hasanpour AH, Sepidarkish M, Mollalo A, Ardekani A, Almukhtar M, Mechaal A, et al. The global prevalence of methicillin-resistant *Staphylococcus aureus* colonization in residents of elderly care centers: A systematic review and meta-analysis. *Antimicrob Resist Infect Control*. 2023;12(1):4.
7. Batiha GES, Alkazmi LM, Wasef LG, Beshbishy AM, Nadwa EH, Rashwan EK. *Syzygium aromaticum* L. (Myrtaceae): Traditional uses, bioactive chemical constituents, pharmacological and toxicological activities. *Biomolecules*. 2020;10(2).
8. Rahmawati ND, Kristina TN, Lestari ES, Hardian H. In vitro testing of clove extracts in inhibiting and killing *Staphylococcus aureus* and *Escherichia coli*. *Diponegoro Med Jour*. 2021;10(1):16–9.
9. Nirmala MJ, Shiny PJ, Raj US, Saikrishna N, Nagarajan R. Chapter 39 - Toxicity of clove (*Syzygium aromaticum*) extract. In: Ramadan MFBTC (*Syzygium aromaticum*), editor. Academic Press; 2022. p. 663–74.
10. Haddad O, Merghni A, Elargoubi A, Rhim H, Kadri Y, Mastouri M. Comparative study of virulence factors among methicillin resistant *Staphylococcus aureus* clinical isolates. *BMC Infect Dis*. 2018;18(1):560.
11. Mihi MR, Roman-Sosa J, Varshney AK, Eugenin EA, Shah BP, Lee HH, et al. Methamphetamine alters the antimicrobial efficacy of phagocytic cells during methicillin-resistant *Staphylococcus aureus* skin infection. *mBio*. 2015;6(6).
12. Dai T, Kharkwal GB, Tanaka M, Huang YY, Bilde Arce VJ, Hamblin MR. Animal models of external traumatic wound infections. *Virulence*. 2011;2(4):296–315.
13. Pratiwi A, Ratnawati R, Kristianto H. The influence of clove bud extract (*Syzygium aromaticum*) on epithelization thickness of incisions wound in the white rat (*Rattus norvegicus*) Wistar strain. 2015;2:135–43.
14. Carvalho MTB, Araújo-Filho HG, Barreto AS, Quintans-Júnior LJ, Quintans JSS, Barreto RSS. Wound healing properties of flavonoids: A systematic review highlighting the mechanisms of action. *Phytomedicine*. 2021;90:153636.
15. Kim YS, Cho IH, Jeong MJ, Jeong SJ, Nah SY, Cho YS, et al. Therapeutic effect of total ginseng saponin on skin wound healing. *J Ginseng Res*. 2011;35(3):360.
16. Scopelliti F, Cattani C, Dimartino V, Mirisola C, Cavani A. Platelet derivatives and the immunomodulation of wound healing. *Int J Mol Sci*. 2022;23(15).
17. Alhurayri F, Porter E, Douglas-Louis R, Minejima E, Wardenburg JB, Wong-Beringer A. increased risk of thrombocytopenia and death in patients with bacteremia caused by high alpha toxin-producing methicillin-resistant *Staphylococcus aureus*. *Toxins* (Basel). 2021;13(10).
18. Soe YM, Bedoui S, Stinear TP, Hachani A. Intracellular *Staphylococcus aureus* and host cell death pathways. *Cell Microbiol*. 2021;23(5):e13317.
19. Arora S, Pal M, Bordoloi M, Nandi SP. Effect of hexane extract of *Syzygium aromaticum* on haematological profile of rats. *J Environ Biol*. 2018;39(3):347–52.
20. Kiritsi D, Nyström A. The role of TGF- $\beta$  in wound healing pathologies. *Mech Ageing Dev*. 2018;172:51–8.
21. Simonetti O, Marasca S, Candelora M, Rizzetto G, Radi G, Molinelli E, et al. Methicillin-resistant *Staphylococcus aureus* as a cause of chronic wound infections: Alternative strategies for management. *AIMS Microbiol*. 2022;8(2):125–37.
22. Ali R, Khamis T, Enan G, El-Didamony G, Sitohy B, Abdel-Fattah G. The healing capability of clove flower extract (CFE) in streptozotocin-induced (STZ-Induced) diabetic rat wounds infected with multidrug resistant bacteria. *Molecules*. 2022;27(7).
23. Vaidyanathan L. Growth factors in wound healing-A review. *Biomed Pharmacol J*. 2021;14(3).