

Surgical treatment options in chronic subdural hematoma: A literature review

Kharisma Ridho Husodo*^{1,2}, Akhmad Suryonurafif^{1,3}

¹Yogyakarta Islamic Hospital of PDHI (Persaudaraan Djama'ah Haji Indonesia), Yogyakarta, Indonesia

²Faculty of Medicine, Brawijaya University, Malang, Indonesia

³Department of Neurosurgery, UGM Academic Hospital, Yogyakarta

Literature Review

ABSTRACT

ARTICLE INFO

Keywords:

chronic subdural hematoma,
surgical treatment,
craniotomy,
burr hole craniotomy,
twist drill craniotomy

*Corresponding author:

kharisma48ridho@gmail.com

DOI: 10.20885/JKKI.Vol15.Iss1.art12

History:

Received: June 14, 2023

Accepted: January 13, 2024

Online: April 29, 2024

Copyright ©2024 Authors.

Chronic subdural hematoma (cSDH) is one of the most common neurosurgery cases in daily practice. Chronic subdural hematoma is clot formation in the subdural space between the dura mater and the arachnoid layer. Due to its progression, clinical presentation of cSDH mostly appears 4 to 8 weeks after a traumatic brain injury. It is the duration needed for the hematoma to grow large enough to cause severe neurological symptoms such as decreased consciousness, hemiparesis, and other signs and symptoms of increased intracranial pressure. There are three main options to treat cSDH. Conservative treatment, surgical treatment, and embolization of the middle meningeal artery (MMA) are widely used to manage this condition. Predominantly, surgical treatments used by neurosurgeons around the world are craniotomy, burr hole (BH) craniostomy, and twist drill (TD) craniostomy. Each of these procedures has advantages and disadvantages. This literature review aimed to consider the characteristics of several treatment options for cSDH and their technique. This review recommends BH craniotomy due to its benefits based on its complication and recurrence rates. Burr Hole craniotomy has a lower complication rate than craniotomy and a lower recurrence rate than TD craniotomy. Twist drill craniotomy is selectively considered for certain patients since this procedure is commonly performed at the bedside without general anesthesia. Craniotomy is recommended as a treatment option for persistent recurrence of cSDH or patients with massive subdural hematoma.

INTRODUCTION

Intracranial hemorrhage (ICH) is a disorder with a high mortality rate worldwide. Based on the bleeding anatomy, ICH can be divided into epidural hemorrhage (EDH), subarachnoid hemorrhage (SAH), subdural hemorrhage (SDH), intraventricular hemorrhage (IVH), and intracerebral hemorrhage, where SDH is the most common.¹ The SDH is formed from the accumulation of blood in the subdural space between the dura mater and the arachnoid layer. The accumulated blood occurs when a vein or artery leaks in that space. Bleeding may occur as a result of acceleration and deceleration of the head, either caused by direct impact/trauma or

non-impact.²

According to the Brain Trauma Foundation (BTF), SDH is classified into acute and chronic types. The BTF defines an acute SDH with hematoma in less than 14 days after traumatic brain injury. Meanwhile, if it occurs more than 14 days after the trauma, it is referred to as chronic SDH.³ The incidence of cSDH ranges from 1.72 to 20.6 per 100,000 persons per year.⁴ Old age, male sex, and history of antiplatelet or anticoagulant consumption are some risk factors of cSDH. Unfortunately, there is no epidemiological research on cSDH in Indonesia.

Currently, there are three most used procedures for treating cSDH worldwide. In Indonesia, only

craniotomy and BH craniotomy are performed to treat cSDH, but twist drill craniostomy is still less well-known. Several cases of hematoma patients were reported to experience complications and recurrence due to inappropriate selection of surgical procedures. This review provides some relevant recommendations to treat cSDH patients based on their conditions to minimize recurrence and complication rates. This review focuses on the surgical options of cSDH, which compares the advantages and disadvantages of each procedure.

METHODS

This literature review summarises current studies on the surgical treatment of cSDH. Articles were from several databases, including PubMed, ScienceDirect, ResearchGate, Springer Journal, and Google Scholar. The combination keywords in the search article were “chronic subdural hematoma”, “surgical treatment”, “craniotomy”, “burr-hole craniostomy”, and “twist drill craniostomy”. The inclusion criteria were articles published in English or Bahasa Indonesia language, publication date between 2013 and 2023, and article type (original articles or review articles). We retrieved data from 39 articles. The selected articles were

identified for analysis.

Etiology and pathogenesis

Some theories of cSDH pathophysiology have been developed significantly year by year until now. At first, cSDH was believed primarily caused by head trauma. A study from Sousa et al. stated that 60,4% of cSDH patients had a trauma event history.⁵ Head trauma can damage the bridging veins in the brain that play a role in the drainage of the bloodstream in the dura mater. This condition causes venous blood to accumulate slowly in the subdural space and distinguishes natural SDH from that of epidural bleeding caused by a tear of the MMA.⁶ At initial disease progression, cSDH might be asymptomatic. It becomes symptomatic after the hematoma is enough to cause mass effect.⁷

The shape of the hematoma seen in cSDH is crescent-like. This finding is consistent with the primary source of its bleeding, the bridging veins adjacent to the medial venous sinuses. Chronic hematoma occurs in the subdural space between the dura mater and the arachnoid layer (Figure 1). The hematoma can enlarge over time and compress the brain.⁶

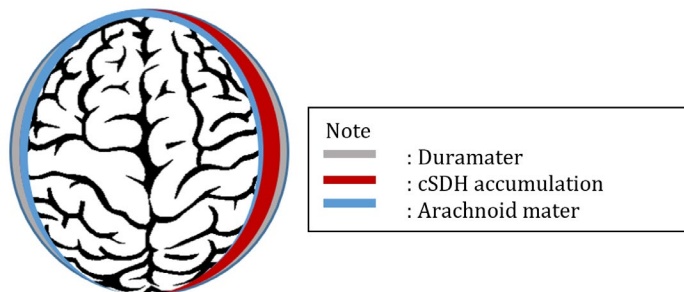


Figure 1. Schematic picture of a chronic subdural hemorrhage.
cSDH: chronic subdural hemorrhage

Inflammation has been hypothesized as a crucial factor in the cSDH progression. Injury response, like trauma or cellular injury, can lead to inflammation. Inflammation aims to trigger the host's immune system to achieve hemostasis, but sometimes harmful to the body itself.⁷ The inflammation process also induces angiogenesis, which affects vascular permeability because of the vascular endothelial growth factor (VEGF) and matrix metalloproteinase (MMP) excess. This process can generate micro-bleeding over time, and when the inflammation becomes chronic, it

may form the hematoma and delay blood to clot perfectly.⁸

The latest well-accepted theory was that cSDH begins with initial bleeding, which crosses the dural cell layer of the dura mater. Hematoma formation from vein tears might fill a space in the subdural space. Because these hematomas form in potential spaces and the bleeding originates from low-pressure venous blood, the blood collection takes more time to expand. This progression interprets why the symptoms of cSDH appear weeks after the initial injury. The inflammatory

response is precipitated and stimulates clot fibrinolysis, granulation tissue assembly, and angiogenic factors release, finally yielding the establishment of “neo-membranes”⁹

Clinical presentation

The cSDH patient can present asymptomatic and symptomatic, even with severe conditions such as seizure and decrease of consciousness. The severity of cSDH depends on the volume of the hematoma, the speed of hematoma enlargement,

the location of the hematoma, and the mass effect generated by the hematoma.¹⁰ Patients with cSDH can have symptoms such as headache, seizures, speech difficulty, decreased memory, dizziness, confusion, and altered mental state with a decreased Glasgow Coma Scale (GCS) score. The site of cSDH in the brain also gives symptoms like hemiparesis or hemiplegia.¹¹ Nouri et al. summarized the signs and symptoms of cSDH as shown in Table 1.

Table 1. Clinical signs and symptoms and radiological findings of chronic subdural hemorrhage⁹

| Clinical Findings | | Radiological Findings |
|--------------------------------|--|---|
| Signs | Symptoms | |
| Pupil examination (anisocoria) | Headache Dizziness | Hematoma with crescent-shaped can be present at the cerebral convexity (one side or both sides) |
| Orientation assessment | Nausea and vomiting | Radiodensities is variable: Hyperacute, within hours |
| Mingizini test | Seizure | Acute, days (hyperdense) |
| Romberg test | Aphasia | Subacute, up to 2 weeks (isodense) |
| Pronator drift (Barre test) | Disorientation Unsteadiness Hemiparesis Tinnitus Malaise and fatigue | Chronic, > 3weeks (hypodense) Brain cortex thickening Hazy gyrus illustration Midline shift and herniation of brain Squashed of ventricular area Development of neo-membrane |

Adjunct examination to diagnose cSDH, which is accepted, is a non-contrast head computer tomography (CT)-scan. This examination reveals a hematoma in subdural space with a crescent-like shape.⁹ When the hematoma appears isodense, the bleeding occurs in subacute, approximately two weeks. The CT scan findings indicate a hypodense hematoma, suggesting blood has settled for at least three weeks.¹¹ The lesion types of cSDH are classified into four types (Figure 2). The first is the homogenous type, the hematoma made of one type of bleeding duration. The second type is the laminar type. It is defined as a hematoma

with a high-density laminar structure running along the inner membrane. The separated type is a hematoma containing two different densities components. The lower-density component is separated from the higher-density component. The last type is the trabecular type, a hematoma with inhomogeneous contents and high-density septa. The septa are formed by fibrosis that runs between the inner and outer membrane on a low-density to isodense background.^{11,12} It is also crucial to measure the mass effect, midline shift, and volume of hematoma to determine the surgery decision and prognosis of the patient.⁶

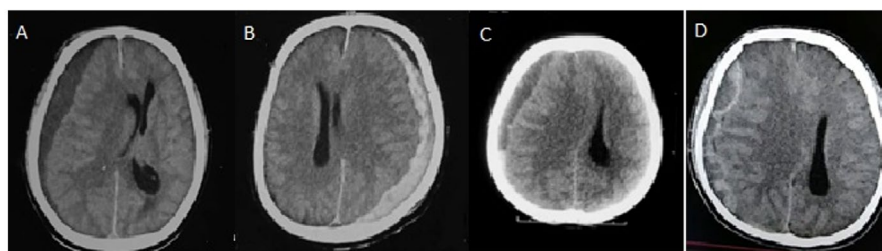


Figure 2. Lesion types of chronic subdural hemorrhage in computer tomography imaging, (A) homogenous type, (b) laminar type, (c) separated type and, (d) trabecular type.

Treatment

Currently, there are no established guidelines for cSDH in Indonesia. The treatment option depends on the clinician and the patient's condition. Treatment options consist of conservative, surgical management, and endovascular approaches.⁶ The criteria of the operable cSDH patient is hematoma thicker than 10 mm or with midline shifted more than 7 mm.¹³ Evidence of worsening condition should be a reevaluation of the head CT scan, and the presence of radiographic progression during conservative treatment is required for surgical treatment.¹³ Middle meningeal artery embolization is a well-known procedure in the endovascular field to treat cSDH.⁹

Conservative treatment for cSDH can only be applied to patients when there is no indication for surgical management, such as intracranial hypertension, mass effect, or cortical irritation. Non-surgical management options for cSDH have limited research evidence supporting their success, with a focus on anti-angiogenic and anti-inflammatory drugs.¹⁴ Some drugs recommended for cSDH conservative treatment were steroid, anti-fibrinolytic, statin class, and Angiotensin-Converting Enzyme (ACE) inhibitors.⁹

Corticosteroid drugs have influential anti-inflammatory and anti-angiogenic effects that can inhibit new blood vessel development. The drug of choice for this class is dexamethasone. This drug is suitable for treating cSDH because it inhibits the inflammatory response and neo-membrane production, therefore preventing clot expansion. On the other hand, dexamethasone should be used cautiously due to its troubling adverse effects, such as inducing a hyperglycemic state in diabetes, increased infection risk, and disturbance in cognition and sleep.^{9,15}

Anti-fibrinolytic, such as tranexamic acid, is usually used to treat cSDH due to its effect for concurrently suppressing the fibrinolytic and inflammatory process, which might settle cSDH. As explained in the pathophysiology, clot fibrinolysis and the inflammation process have contributed to inducing the development of chronic subdural hematoma. Tranexamic acid also may inhibit the cSDH development at the initial stages after injury.¹⁵ A study by Yang et al. showed that tranexamic acid also has a role in post-surgical treatment because it markedly eased the resorption of remaining hematoma in cSDH. Tranexamic acid medication

is considered effective in lowering recurrence probability by accelerating cSDH resolution in some patients.¹⁶

There was a report that statin-class drugs were effective for cSDH treatment. Atorvastatin, one of the statin drugs, acts by blocking 3-hydroxy-3-methyl glutaryl coenzyme-A reductase and lowering the level of low-density lipoprotein cholesterol, but this evidence was weak because only three studies reported, including a systematic review.¹⁷ An animal study conducted by Araujo et al., had shown that atorvastatin in low doses (3 mg/kg/day) could lessen inflammatory response and angiogenesis.¹⁸ The mechanisms of atorvastatin in treating cSDH are by lowering the activation of MMP and inhibiting VEGF.¹⁹

The last option of conservative drugs is ACE inhibitors. These drugs reduce the VEGF-production and inflammation process, as well as neovascularization and fluid leakage into the subdural space so cSDH is more predicted to be resolved. However, the ACE inhibitor drug does not significantly affect markedly the cSDH progression.²⁰ Until today, there are no strong supporting results in the literature.⁹

The surgical treatment decision is influenced both by the lesion of the hematoma through a radiographic examination and the patient's neurological condition. Some procedures of surgery in cSDH include craniotomy, craniectomy, twisted drill (TD) craniostomy (with catheter drainage or spontaneous hematoma efflux), BH craniostomy, and endoscopic removal method.²¹ The most frequently used surgical procedures are craniotomy, BH craniostomy, and TD craniostomy. Each surgical procedure has its strengths and weaknesses. In brief, TD craniotomy is the opening of the skull with only up to 5 mm in diameter, while BH craniotomy is the skull opening method with up to 30 mm, and craniotomy has a larger opening site incision.²²

From these surgical treatment options, Lee reviewed their advantages and disadvantages in the table (Table 2).²¹ Craniotomy has the highest complication rate because it requires a wide surgical site and general anesthesia. The BH craniostomy and TD craniostomy have low complication rates due to their minimal surgical sites. Lega et al. had done a Monte Carlo simulation on meta-analysis data and found that BH craniotomy was superior in efficiency to be used for surgical drainage of

cSDH without complications due to its balance between advantages in terms of low recurrence rate, operation location (can be done both in the

operating room or bedside), and operation time. In addition, the complication rate was lower than that of TD craniostomy.²³

Table 2. Characteristic of chronic subdural hemorrhage surgical treatment options²¹

| Surgical Procedure | Craniotomy | Burr hole | Twisted Drill |
|--------------------|----------------|---------------------------|---------------------------|
| Anaesthesia | General | General or local | Local or general |
| Procedure | Operating room | Operating room or bedside | Bedside or operating room |
| Surgery duration | Around 3 hours | Around 1 hour | Less than 1 hour |
| Complications | High | Low | Low |
| Recurrence | Low | Slightly high | High |
| Surgical site | Very large | Up to 30 mm | Up to 3 mm |

Craniotomy treatment is one of the conventional surgical procedures to treat cSDH, and this method is still common in the neurosurgery field.²⁴ Before surgery, the patient is supine, with all pressure points padded appropriately. Revelation of the calvarium side during operation can be encouraged by placing a shoulder bump under the ipsilateral side. Head fixation is facilitated by applying a doughnut pillow or horseshoe head holder. This procedure is likely the same as treatment for acute SDH.²⁵ This procedure has excellence in the management of cSDH with trabecular and laminar lesion types because it allows the operator to evacuate the hematoma and its septa with a large opening site. Thus, a craniotomy may be necessary in cases that persistently recur after other procedures.²⁴ However, the shortfalls of craniotomy are the use of general anesthesia, the need for a ventilator post-surgery, the large size of the surgical site, and the high risk of infection at the surgical site.²⁵

A craniotomy is a surgical procedure to remove the skull segment to uncover the brain. The operation begins with an incision approximately 1 cm below the superior temporal line, extending superiorly about 2 cm lateral to midline in the parietal region, and 1cm posterior to the coronal suture. Bleeding control is achieved using scalp clips after temporalis incisions and a retractor is placed to see the field.²⁶ Burr holes were placed at the apices of the skull at the incision site, and then the skull and underlying dura below were separated using a footplate attachment. The skull bone is removed from the place and placed in an antibiotic or sterile solution. The holes are made by drilling circumferentially at the edge of the craniotomy site, as well as the epidural

tacking process. Dura is opened using a small blade, no. 11, followed by tenotomy scissors until the dura mater is exposed. The outer membrane of the dura may be present when opening the dura. Hematoma evacuation was performed after coagulation of the surface of the membrane and opening the dura, although the hematoma will be expelled immediately. Maximize the evacuation by irrigating the subdural space with a normal saline solution. Electrocautery or bipolar pens are used to stop the bleeding along the membrane and cortical surface.²⁶ In the subdural space, the drain is set down to evacuate the remaining blood after surgery. Then, some stitches are used to close the dura mater.²⁵

Burr-hole craniotomy was commonly carried out using double BH. However, a single BH has the same level of efficacy as multiple BH using reducing symptoms and recurrence, and the choice depends on the neurosurgeon and the volume and type of SDH lesion.²⁷ Both general and local anesthesia options can be applied in BH craniotomy, depending on the operator's tendency, patient condition, and compliance.²¹ The advantages of BH craniotomy compared to craniotomy are the shorter length of stay, the shorter surgery duration, and the more efficient operative cost.²¹ Meanwhile, BH craniotomy has a slightly higher recurrence rate than craniotomy.²⁸ Therefore, BH craniotomy is not recommended as cSDH treatment with trabecular or laminar lesion types.²³

A BH craniotomy procedure uses a handheld drill attached to a BH site. The drill is positioned perpendicular to the skull and turned rapidly. Then, a visual inspection is needed to confirm the breach of the inner cortex. The neurosurgeon

can utilize a sharp bone curette or a round burr to expand the burr holes. Bone wax is installed on the rims of the burr hole.²⁹ The BH craniotomy requires two holes: the first BH is anterior, in front of the coronal suture, and the second one is placed posteriorly on the tuber parietalis, approximately 8 cm posterior from the anterior BH (Figure 3). Both BH are placed cranially to the superior temporal line to keep away the risk of damaging potential brain areas such as the operculum or primary motor cortex. When the BH position is more medially and superior, the bridging vein has a higher risk of injury, and passive hematoma outflow has lower strength.⁹

After opening the dura, there may be a spontaneous outflow of liquid hematoma. It is usually darker than normal blood. Otherwise, a membrane is present as expected. This membrane may be visible and should be coagulated using an electrocautery or bipolar instrument and cut with a sharp blade No. 11.30,31 Dural membrane coagulation is needed to prevent bleeding into the

subdural place.²⁶ After the initial liquid hematoma is evacuated, inspect each BH site. A small catheter for drainage is placed with landmarks shown in Figure 3. Irrigation is performed with sterile normal saline using a 10 ml or 20 ml syringe. The syringe is connected to the open end of the catheter and then elevated to allow the solution to flow into subdural space. Every burr hole is monitored to verify if there is a connection between both BH sites.⁹ Irrigation is continued until the coming-out water is clear. The BH craniotomy method is continued with drain placement. A small drain or ventricular catheter is assembled into subdural space at the frontal, with a depth at the parietal burr hole of approximately.²⁶ Carefully advance the depth of the drain if there is any resistance. Sites of BH are irrigated with normal saline to get the air out of the subdural chamber. The aperture of the dura mater should be enclosed using a gelatin sponge to prevent air or blood from entering the space of the subdural.²⁷

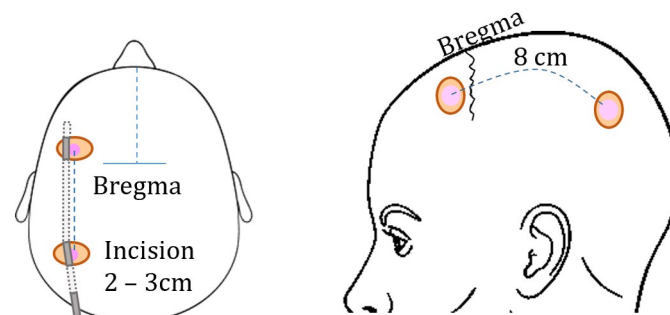


Figure 3. Sketch of a top and side view of anatomical marker in Burr hole craniotomy.

For cSDH, particularly in elderly patients, TD craniotomy is a minimally invasive, secure, and quick procedure treatment option.³² The TD craniotomy procedure can be performed at the bedside or in the operating room.⁹ Considering the difference between BH craniotomy and TD craniotomy, an elderly patient with homogenous cSDH who meets the hazardous criteria for using total unconscious anesthesia should be managed with TD craniotomy with conscious anesthesia.³³ A study by Jablawi et al. confirmed that the TD craniotomy procedure is effective only for smaller hematoma volumes, while larger hematoma had more treatment failures in TD craniotomy.³² However, this study asserted that the TD craniotomy method is a beneficial provisional emergency treatment while awaiting

the definitive surgical treatment, and this method is effective as a treatment for cSDH without general anesthesia. This study also stated that TD craniotomy had advantages in being minimally invasive and safer (minimal complication) to treat cSDH.³² The weakness of TD craniotomy is its higher recurrence rates than BH craniotomy and craniotomy.²¹ The TD craniotomy requires a slightly shorter hospital stay and a shorter duration of surgery than the BH craniotomy method.³⁴ Among the three procedures above, TD craniotomy is the most efficient procedure to treat cSDH.³²

This procedure begins with a small incision and sterile conditions at the marked point where the curvature peaks of the accumulated blood (Figure 4A). The estimated point of TD craniotomy

was drilled using a hand drill (Figure 4B). After uncovering the dura mater, a standard peripheral venous access catheter is used to puncture over the dura mater (Figure 4C).³² Immediately, the hematoma fluid is drained through the catheter and piled up in a sterile container to evaluate the volume and characteristics of the blood. To ease the drainage process, the patient is in the Trendelenburg position. The irrigation of subdural space is carried out with normal saline (NaCl 0.9%) at body temperature, and flushing should be discontinued when the liquid that comes out is clear.³³ The punctured catheter is revoked slowly to avoid cortical injury due to a procedural mistake when irrigation is about to be finished.³² The drilled hole is covered to prevent air from entering the brain, and the opening site is closed by simple suturing.²⁶

Nowadays, TD craniotomy has some

modification methods that some authors have found to improve safety, simplicity, and effectiveness. One of them is a hollow screw attached to a drilled hole in the cranium and then connected to a closed drainage system.³⁵ A modification using the subdural evacuating port system (SEPS) and a bulb suction apparatus with negative pressure will enable more advantages in brain re-expansion.³⁶ Several authors introduced drilling angle adjustment to minimize the brain perforation risk to avoid this complication, and this modification is the most interesting.³⁷ A three-way stopcock modification technique gives beneficence in rapid, controlled, stepwise irrigation with a low risk of pneumocephalus.³³ Trephination craniotomy, either by BH or TD, is currently the preferred treatment for symptomatic individuals.⁹

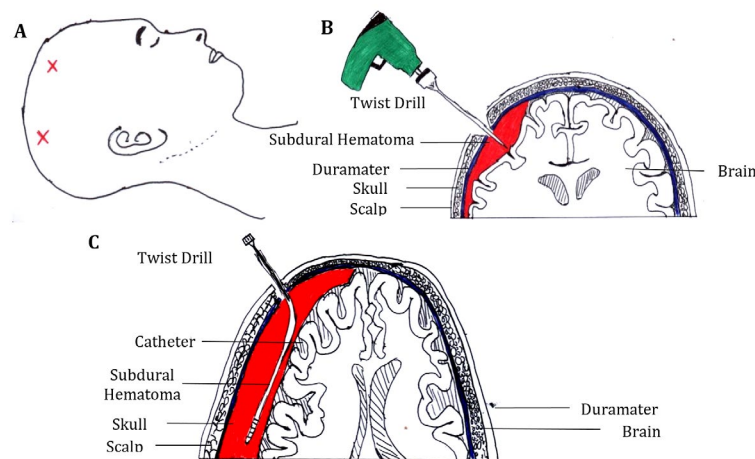


Figure 4. The twist drill craniostomy procedure; (A) A 5–6 mm skin incision at the marked point of the hematoma; (B) A twist drill is inserted through the scalp incision perpendicular to the skull, and the dura mater is exposed. (C): A catheter is placed over the dura mater.

Embolization of the MMA is an alternative method for cSDH. The MMA embolization aims to prevent hematoma enlargement, although it interferes with the blood flow to the external area.^{37,38} This procedure prevents the development of neovascularization and bleeding granulation tissue (neo-membranes) due to inflammation. A study reported that neuro-vascularization in cSDH is flowed by some branch blood vessels of the MMA. This procedure is a proven anti-angiogenic transformation to avoid rebleeding and inflammation.³⁹ The disadvantages of MMA embolization are the recurrence rate and the slow rate of symptom improvement due to the absence of hematoma evacuation, which can decrease

intracranial pressure.⁹

Several drugs used in embolization are polyvinyl alcohol (PVA), N-butyl-2-cyanoacrylate, Onyx, coils, and gelatin. All of them have no differences in the outcome. Most studies on MMA embolization have used PVA particles suspended in an opaque carrier solution.⁴⁰ The procedure can be carried out under total or moderate anesthesia, depending on the tendency of the neurosurgeon. The common femoral artery is the regular entry point to insert an arterial catheter, but another alternative line is the radial artery when the first artery route can be performed due to other medical conditions.⁴⁰ The operator then advances the inserted catheter to the common carotid artery (CCA), and with guidance,

a micro-catheter is directed into the MMA.³⁸ The next step is carrying out the MMA angiography to visualize the MMA anatomy and its branches that contribute to cSDH development.⁴⁰ Anatomically, the infratemporal fossa from the first portion of the internal maxillary artery is the MMA area, and the sphenoidal, frontal, parietal, and petrosquamosal branches of the MMA extend from anterior to posterior.³⁸ Several branches are selected to be catheterized for embolization, or it can be executed proximally before branch points with the volume and spot of the hematoma in consideration. The operator should be more careful in this procedure due to the many anastomotic connections of MMA, which supply several cranial nerves.⁴⁰ The embolization procedure is executed by infusing the drug at a slow pace (diluted PVA about 150–250 microns) until antegrade circulation or reflux around the catheter tip is at equilibrium.³⁸ An MMA angiography evaluation is performed to see if circulation into the distal branches of the MMA has terminated. The patency of intracranial blood vessels should be confirmed by performing another CCA angiography, and then the catheter can be retracted.⁴⁰

Hemostasis is achieved by using a closure tool and manual compression. For observation, patients should be treated in the recovery room overnight, and the next day, a head CT scan is evaluated. After discharge from the hospital, regular rehabilitation to restore the patient's quality of life is crucial. Patients should also be informed to stay away from risk factors that lead to the recurrence of cSDH. The evaluation of the head CT scan is planned for two to six weeks post-operation.³⁸

The most basic principle that distinguishes surgical treatment from MMA embolization is that the main aim of MMA embolization is to restrict the growth of the hematoma, while surgery is to draw out or evacuate the hematoma.⁶ Based on the arguments above, the two strategies, MMA embolization and surgical management, have their objectives and characteristics.

CONCLUSION

Chronic subdural hematoma is a disorder that mostly occurs in the elderly and needs to be treated immediately to minimize the morbidity and mortality of patients. There are many theories of cSDH pathogenesis, including the rupture of bridging veins due to minor head trauma and

an inflammatory response that leads to neo-membrane formation or micro-bleeding due to blood vessel fragility. There are three main options for treating cSDH: conservative treatment, surgical treatment, and MMA embolization. Surgical procedures that are used by many neurosurgeons overall are craniotomy, BH craniotomy, and TDC. Each procedure has its indications, advantages, and disadvantages. In this paper, we conclude that BH craniotomy has more advantages as an effective treatment option for cSDH due to its low recurrence and low complication rate.

CONFLICT OF INTEREST

The authors stated that there is no conflict of interest.

ACKNOWLEDGEMENTS

Not applicable.

AUTHOR CONTRIBUTIONS

Concepts, design, definition of intellectual content, literature search, data acquisition, data analysis, manuscript preparation, manuscript editing, manuscript review; KRH. Concepts, definition of intellectual content, data analysis, manuscript review; AS.

LIST OF ABBREVIATIONS

ICH: Intracranial hemorrhage; EDH: epidural hemorrhage; SAH: subarachnoid hemorrhage; SDH: subdural hemorrhage; IVH: intraventricular hemorrhage; cSDH: chronic subdural hematoma; CT: Computed Tomography; GCS: Glasgow coma scale; MMA: Middle Meningeal Artery; ACE: Angiotensin-Converting Enzyme; VEGF: Vascular Endothelial Growth Factor; MMP: matrix metalloproteinase; TD: twisted drill; BH: Burr Hole; MRI: Magnetic Resonance Imaging; SEPS: subdural evacuating port system; NaCl: Sodium Chloride; PVA: polyvinyl alcohol; CCA: common carotid artery

REFERENCES

1. Borja MJ, Guarnizo A, Lustrin ES, Mehuron T, Zhu B, Sapozhnikov S, et al. Neurological emergencies in geriatric patients. in *Emergency imaging of at-risk patients*. Elsevier: 2023. 12–35 p. ISBN: 978-0-323-87661-2. DOI:10.1016/B978-0-323-87661-2.00003-8.
2. Greenberg MS. *Handbook of neurosurgery*.

- New York: Thieme Medical Publisher; 2019.
3. Brain Trauma Foundation. Guidelines for the surgical management of TBI [Internet]; 2006 [Cited 2023 May 12]. Available from: <https://braintrauma.org/coma/guidelines/guidelines-for-the-surgical-management-of-tbi>
 4. Yang W, Huang J. Chronic subdural hematoma: Epidemiology and natural history. *Neurosurg Clin N Am.* 2017; 28(2): 205-10. DOI: 10.1016/j.nec.2016.11.002.
 5. Iliescu IA. Current diagnosis and treatment of chronic subdural haematomas. *J Med Life.* 2015; 8(3): 278-284. <https://pubmed.ncbi.nlm.nih.gov/26351527/>
 6. Usman FS, Mulyono GA, Rilianto B, Irawan H, Irawan N, Dinata GS, et al. Manajemen subdural hematoma kronis: Sebuah paradigma baru strategi neurointervensi. *Neurona.* 2021; 38 (4): 315-322. <https://ejournal.neurona.web.id/index.php/neurona/article/view/271/208>
 7. Edlmann E, Giorgi-Coll S, Whitfield PC, Carpenter KLH, Hutchinson PJ. Pathophysiology of chronic subdural haematoma: Inflammation, angiogenesis and implications for pharmacotherapy. *J. Neuroinflammation.* 2017; 14(1):108. DOI: 10.1186/s12974-017-0881-y.
 8. Weigel R, Schilling L, Krauss JK. The pathophysiology of chronic subdural hematoma revisited: Emphasis on aging processes as key factor. *Geroscience.* 2022; 44(3):1353-1371. DOI: 10.1007/s11357-022-00570-y.
 9. Nouri A, Gondar R, Schaller K, Meling T. Chronic subdural hematoma (cSDH): A review of the current state of the art. *Brain Spine.* 2021;1:100300. DOI: 10.1016/j.bas.2021.100300.
 10. Rauhala M, Luoto TM, Huhtala H, Iverson GL, Niskakangas T, Öhman J, et al. The incidence of chronic subdural hematomas from 1990 to 2015 in a defined Finnish population. *J Neurosurg.* 2019; 132(4):1147-1157. DOI: 10.3171/2018.12.JNS183035.
 11. Yadav YR, Parihar V, Namdev H, Bajaj J. Chronic subdural hematoma. *Asian J Neurosurg.* 2016; 11(4):330-342. DOI: 10.4103/1793-5482.145102.
 12. Harada Y, Yoshida K, Nojiri S, Kurihara Y, Kobayashi H, Arai H. Identification of chronic subdural hematoma types most responsive to Goreisan, Kampo medicine: A retrospective study. *J Clin Neurosci.* 2020; 78:198-202. DOI: 10.1016/j.jocn.2020.04.063.
 13. Mehta V, Harward SC, Sankey EW, Nayar G, Codd PJ. Evidence based diagnosis and management of chronic subdural hematoma: A review of the literature. *J Clin Neurosci.* 2018; 50:7-15. DOI: 10.1016/j.jocn.2018.01.050.
 14. Fernandes de Oliveira M. Chronic subdural hematomas and pursuit of nonsurgical treatment alternatives. *World Neurosurg.* 2019; 126:481-483. DOI: 10.1016/j.wneu.2019.03.151.
 15. Iorio-Morin C, Blanchard J, Richer M, Mathieu D. Tranexamic acid in chronic subdural hematomas (TRACS): Study protocol for a randomized controlled trial. *Trials.* 2016; 17(1):235. DOI: 10.1186/s13063-016-1358-5.
 16. Yang K, Kim KH, Lee HJ, Jeong EO, Kwon HJ, Kim SH. Role of adjunctive tranexamic acid in facilitating resolution of chronic subdural hematoma after surgery. *J Korean Neurosurg Soc.* 2023; 66(4):446-455. DOI: 10.3340/jkns.2022.0200.
 17. Qiu S, Zhuo W, Sun C, Su Z, Yan A, Shen L. Effects of atorvastatin on chronic subdural hematoma: A systematic review. *Medicine (Baltimore).* 2017; 96(26): e7290. DOI: 10.1097/MD.00000000000007290.
 18. Araújo FA, Rocha MA, Mendes JB, Andrade SP. Atorvastatin inhibits inflammatory angiogenesis in mice through down regulation of VEGF, TNF-alpha and TGF-beta1. *Biomed Pharmacother.* 2010; 64(1): 29-34. DOI: 10.1016/j.biopha.2009.03.003.
 19. Li T, Wang D, Tian Y, Yu H, Wang Y, Quan W, et al. Effects of atorvastatin on the inflammation regulation and elimination of subdural hematoma in rats. *J Neurol Sci.* 2014; 341(1-2): 88-96. DOI: 10.1016/j.jns.2014.04.009.
 20. Stejskal P, Vaverka M, Trnka S, Hampl M, Hrabalek L. Effect of angiotensin converting enzyme inhibitors on the development of chronic subdural haematoma. *Biomed Pap Med Fac Univ Palacky Olomouc Czech Repub.* 2021; 165(2): 175-178. DOI: 10.5507/bp.2020.029.
 21. Lee KS. How to Treat chronic subdural hematoma? Past and now. *J Korean Neurosurg Soc.* 2019; 62(2):144-152. DOI: 10.3340/jkns.2018.0156..
 22. Lee SJ, Hwang SC, Im SB. Twist-drill or burr hole craniostomy for draining chronic sub-

- dural hematomas: How to choose it for chronic subdural hematoma drainage. *Korean J Neurotrauma*. 2016; 12(2):107-111. DOI: 10.13004/kjnt.2016.12.2.107.
23. Lega BC, Danish SF, Malhotra NR, Sonnad SS, Stein SC. Choosing the best operation for chronic subdural hematoma: A decision analysis. *J Neurosurg*. 2010; 113(3): 615-21. DOI: 10.3171/2009.9.JNS08825.
 24. Ram S, Visvanathan K. Mini-craniotomy for subdural hematoma – Experience in a tertiary care centre. *Interdiscip. Neurosurg*. 2020; 19: 100623. <https://doi.org/10.1016/j.inat.2019.100623>
 25. Abecassis IJ, Kim LJ. Craniotomy for treatment of chronic subdural hematoma. *Neurosurg Clin N Am*. 2017; 28(2): 229-237. DOI: 10.1016/j.nec.2016.11.005.
 26. Ulman JS, Raksin PB. *Atlas of emergency neurosurgery*. New York: Thieme; 2015.
 27. Sale D. Single versus double burr hole for drainage of chronic subdural hematoma: Randomized controlled study. *World Neurosurg*. 2021; 146: e565-e567. DOI: 10.1016/j.wneu.2020.10.140.
 28. Cofano F, Pesce A, Vercelli G, Mammi M, Massara A, Minardi M, et al. Risk of recurrence of chronic subdural hematomas after surgery: A multicenter observational cohort study. *Front Neurol*. 2020; 11: 560269. DOI: 10.3389/fneur.2020.560269.
 29. Fernández-deThomas RJ, Munakomi S, De Jesus O. Craniotomy. In: *StatPearls* [Internet]; 2023 [Cited 2023 May 18]. Available from: <https://www.ncbi.nlm.nih.gov/books/NBK560922>.
 30. Májovský M, Netuka D, Beneš V, Kučera P. Burr-hole evacuation of chronic subdural hematoma: Biophysically and evidence-based technique improvement. *J Neurosci Rural Pract*. 2019; 10(1): 113-118. DOI: 10.4103/jnrp.jnrp_167_18.
 31. Unterhofer C, Freyschlag CF, Thomé C, Ortler M. Opening the internal hematoma membrane does not alter the recurrence rate of chronic subdural hematomas: A prospective randomized trial. *World Neurosurg*. 2016; 92:31-36. DOI: 10.1016/j.wneu.2016.04.081.
 32. Jablawi F, Kweider H, Nikoubashman O, Clusmann H, Schubert GA. Twist drill procedure for chronic subdural hematoma evacuation: An analysis of predictors for treatment success. *World Neurosurg*. 2017; 100:480-486. DOI: 10.1016/j.wneu.2017.01.037.
 33. Hanalioglu S, Bozkurt G, Isikay I, Mammadkhanli O. A simple and effective modified technique of twist drill craniostomy for bedside drainage and irrigation of chronic subdural hematoma: Technical and clinical study. *Clin Neurol Neurosurg*. 2020; 199:106262. DOI: 10.1016/j.clineuro.2020.106262.
 34. Xu CS, Lu M, Liu LY, Yao MY, Cheng GL, Tian XY, et al. Chronic subdural hematoma management: Clarifying the definitions of outcome measures to better understand treatment efficacy - a systematic review and meta-analysis. *Eur Rev Med Pharmacol Sci*. 2017; 21(4): 809-818. PMID: 28272701.
 35. Wei Z, Jiang H, Wang Y, Wang C. Effect of twist-drill craniostomy with hollow screws for evacuation of chronic subdural hematoma: A meta-analysis. *Front Neurol*. 2022; 12: 811873. DOI: 10.3389/fneur.2021.811873.
 36. Shafique MA, Mustafa MS, Haseeb A, Arbani N, Kumar A, Perkash S, et al. Subdural evacuating port system for chronic subdural hematoma: A systematic review and meta-analysis of clinical outcomes. *Egypt. J. Neurosurg*. 2023; 38 (76). <https://doi.org/10.1186/s41984-023-00251-8>
 37. Szmuda T, Kierońska S, Słoniewski P, Dzierżanowski J. Modified bedside twist drill craniostomy for evacuation of chronic subdural haematoma. *Wideochir Inne Tech Maloinwazyjne*. 2019; 14(3): 442-450. DOI: 10.5114/wiitm.2019.83001.
 38. Link TW, Boddu S, Paine SM, Kamel H, Knopman J. Middle meningeal artery embolization for chronic subdural hematoma: A series of 60 cases. *Neurosurgery*. 2019; 85(6): 801-807. DOI: 10.1093/neuros/nyy521.
 39. Ban SP, Hwang G, Byoun HS, Kim T, Lee SU, Bang JS, et al. Middle meningeal artery embolization for chronic subdural hematoma. *Radiology*. 2018; 286(3): 992-999. DOI: 10.1148/radiol.2017170053.
 40. Désir LL, D'Amico R, Link T, Silva D, Ellis JA, Doron O, et al. Middle meningeal artery embolization and the treatment of a chronic subdural hematoma. *Cureus*. 2021; 13(10): e18868. DOI: 10.7759/cureus.18868.