

Histopathological diagnostic criteria of barrett esophagus and its association with endoscopy findings

Ukhti Jamil Rustiasari*¹, Handjari DR²

¹Pathology Anatomy Department, Medical Faculty, Universitas Islam Indonesia, Yogyakarta

²Pathology Anatomy Department, Medical Faculty, Universitas Indonesia, Jakarta

Original Article

ABSTRACT

ARTICLE INFO

Keywords:

acute pulmonary edema
chronic kidney disease
kerley line

*Corresponding author:

ukhti.rustiasari@gmail.com

DOI : 10.20885/JKKI.Vol8.Iss1.art7

History:

Received : January 20, 2017

Accepted : April 3, 2017

Online : April 26, 2017

Background: In the last decades, the incidence of esophageal adenocarcinoma has significantly increased. Barrett Esophagus (BE) is widely known as a precursor lesion of esophageal adenocarcinoma, and it could increase the risk of adenocarcinoma to 30-120 times higher than non-BE patient. The controversy about BE definition is still a problem amongst pathologist. BE is defined as the transition of normal esophageal squamous epithelium into metaplastic columnar epithelium that can be seen through endoscopy at the upper region of gastroesophagus transitional area, and confirmed with histological examination.

Objective: To re-evaluate histopathological presentation of BE and the classification of dysplasia as well as its association with clinical finding in the form of endoscopy results.

Methods: Clinical and histopathological data of 71 cases of BE was collected and re-evaluated based on British Society of Gastroenterology Guidelines 2005 criteria, as well as re-evaluating the grade of dysplasia based on WHO Classification of tumours of the digestive system 2010.

Results: 51 cases of BE were obtained with male:female ratio 33:18 patients. BE cases were predominated by 51-60 years old age group, in which the mean of patients age was 55 years old. The results of dysplasia grade re-evaluation showed 72,55% non-dysplasia BE case, 3,9% was BE indefinite; 23,53% was BE with low grade dysplasia; and 1,97% was BE with high grade dysplasia. There were 15 cases (21,12%) that were changed in diagnosis, from BE to non-BE cases.

Conclusion: The diagnosis of BE could be made if there are compatibility between endoscopy examination and histopathological examination, in which BE presentations was found, either in category 1, 2 or 3 based on British Society of Gastroenterology Guidelines 2005 and endoscopy indicated suspicion of BE. Changes in diagnosis of BE cases into non-BE cases could happen not because there are incompatibilities of the results of these examinations. This might happen due to nescience regarding the importance of the results of endoscopy examination and its compatibility with the results of histopathological examination.

Latar Belakang: Insiden adenokarsinoma esophagus dalam beberapa dekade terakhir telah mengalami peningkatan yang signifikan. Barrett Esophagus (BE) diketahui sebagai lesi prekursor adenokarsinoma esophagus dapat meningkatkan risiko pasien menjadi adenokarsinoma sebesar 30-120 kali dibandingkan pasien tanpa BE. Kontroversi mengenai definisi BE masih menjadi masalah dikalangan para ahli patologi.

BE didefinisikan sebagai penggantian lapisan epitel gepeng esophagus normal oleh metaplasia epitel kolumnar yang dapat terlihat secara endoskopi pada bagian atas peralihan gastroesophagus dan dikonfirmasi dengan hasil pemeriksaan histologik.

Tujuan: Menilai ulang gambaran histopatologik BE dan derajat displasia serta kaitannya dengan temuan klinis berupa hasil pemeriksaan endoskopi.

Metode: Dilakukan pengumpulan data klinis dan histopatologik terhadap 71 kasus dengan keterangan BE dan melakukan evaluasi diagnosis BE berdasarkan British Society of Gastroenterology Guidelines 2005, serta menilai ulang derajat displasia berdasarkan WHO Classification of tumours of the digestive system 2010.

Hasil: Diperoleh 51 case BE dengan jumlah kasus laki-laki:wanita sebanyak 33:18 pasien. Kasus BE didominasi oleh kelompok usia 51-60 tahun dengan rata-rata usia pasien 55 tahun. Hasil penilaian ulang derajat displasia menunjukkan 72,55% merupakan kasus BE tanpa displasia, 3,9% adalah kelompok kasus BE indefinite, 23,53% adalah kasus BE displasia ringan dan sebanyak 1,97% adalah kasus BE displasia keras. Sebanyak 15 kasus (21,12%) mengalami perubahan diagnosis dari BE menjadi kasus tanpa BE.

Kesimpulan: Penegakan diagnosis BE dapat dilakukan apabila terdapat kesesuaian antara hasil pemeriksaan histopatologik dan hasil endoskopi dengan didapatkannya gambaran histopatologik BE kategori 1, 2 atau 3 berdasarkan British Society of Gastroenterology Guidelines 2005 dan hasil endoscopy yang mencurigai adanya suatu BE. Perubahan diagnosis kasus BE menjadi kasus bukan BE terjadi karena ketidaksesuaian antara kedua hasil tersebut. Hal ini dapat terjadi karena adanya ketidaktahuan dalam menilai pentingnya hasil pemeriksaan endoskopi dengan kesesuaiannya terhadap hasil pemeriksaan histopatologik.

INTRODUCTION

Barrett Esophagus (BE) has been acknowledged as the precursor lesion of esophageal adenocarcinoma.¹ The incidence of esophageal adenocarcinoma, eventhough still considered quiet low, but has continued to increase within the current years. In the United States, the incidence of esophageal adenocarcinoma had increased from 3,5:1.000.000 in 1973 to 25,6:1.000.0000 in 2006.² Barrett Esophagus would increase the risk of esophageal adenocarcinoma as much

as 30-120 times when compared to patients without BE.³ It was reported in a study about BE surveillance that 4% (9/212) BE patients, who took part in 13 years surveillance program, developed esophageal adenocarcinoma.⁴ The increase of BE incidence in the United States and European countriesd are in coherence with the increase of esophageal adenocarcinoma incidence, however only less than 10% patients were diagnosed with mucosal metaplasia prior to malignancy diagnosis.⁵

The universal definition of BE is still a controversy even until now, thus there are a lot of confusion and difficullties in comparing BE researches. Practical Committee of American College of Gastroenterology had established a standard definition of BE in 2008. BE is described as an epithelial changes in transient squamocolumnar epithelium, proximal from gastroesophageal transition, which could be diagnosed by columnar mucous finding in endoscopy, and confirmed with intestine metaplasia (IM) in esophageal biopsy.⁶ They stated that the prescence of IM is a sign of pre-malignancy lession for esophageal adenocarcinoma.

British Society of Gastroenterology (BSG) Guidelines for Barrett esophagus, described it as the prescence of columnar cell metaplasia (Columnar Lined Oesophagus/CLO) at the upper region of gastroesophageal transition, which should be confirmed or supported by histological analysis. The diagnosis of BE could be made when columnar metaplasia segment is found during endoscopy examination which occur as reddish corrugation as the result of reflux esophagitis, similar to the pink line of salmon flesh.⁷

Pathology experts in United States and Europe-Japan is currently on debate about how far the effect of IM in CLO would increase the risk of esophageal adenocarcinoma. The pathological experts in Europe and Japan believe that the abscence of MI is only a reflection of sampling error. Some researchers stated that the prescence of columnar cell metplasia (CLO) is biologically the same as intestinal metaplasia which could

be seen by similar molecular changes in true goblet cells population. This result supported the notion that the presence of pseudogoblet cells in CLO might also have the same risk in evolving into neoplasia, even without clear goblet cells.⁸ According to this fact and consideration, we gravitate more to the notion of pathological experts in Europe and Japan in terms of BE diagnostic criteria

The accuracy of identifying patients with BE rely on valid histopathological and clinical diagnostic. Upper gastrointestinal tract (UGIT) endoscopy or esophagogastroduodenoscopy /EGD is a standard examination for Gastroesophageal Reflux Disease/GERD diagnostic. One of the role of EGD is to confirm the presence of esophageal damage, such as erosion, ulceration, stricture, BE, or malignancy; in addition to exclude other UGIT disorders. Endoscopy could also determine the severity of mucosal break using modified Los Angeles classification or Savary-Miller, and continued with biopsy if BE or malignancy is suspected.⁹ The reliability of BE diagnosis is predetermined by endoscopy findings which would indicate the presence of suspected BE and would be supported by adequate sampling technique.¹⁰

Patients with BE has increased risk of progressing into dysplasia and adenocarcinoma. Most esophageal adenocarcinoma cases are predicted to be related to BE accompanied with dysplasia. Dysplasia is not only a marker of possible adenocarcinoma, but also clearly identified as preinvasive lesion.^{11,12} Histopathological examination is, until today, the basis of clinical diagnostic evaluation in order to evaluate the risk of progression into esophageal adenocarcinoma in BE patients.¹³ This research aimed to determine the prevalence and patients demography in BE patients from 2008-2012, as well as re-evaluating histopathological finding of BE and the severity of dysplasia, in relation with clinical findings from endoscopy examination.

METHODS

This research is a descriptive study. Data's of demographic, clinical, and histopathological

characteristics are presented in tables and graphics. Research samples were obtained from the archive of Pathology Anatomy Department of FKUI/RSCM from 2008 until 2012 (5 years research period). Case finding was done using topography code (C15.5, C15.9) and Barrett esophagus keyword.

All registration forms and histopathological slides that were consistent with keywords and topography code was gathered. Forms documentation was done including the age, gender, clinical diagnostic, EGD results, and histopathological diagnostic. Patients clinical data's in the form of obtained EGD results were then equipped with additional data's from Gastroenterology division of Internal Medicine Department FKUI/RSCM.

Inclusion criteria was all BE cases from both histopathological and clinical diagnostic that was made during 2008 until 2012. Cases with no samples slides or paraffin blocks, as well as those with incoherence clinical diagnostic were excluded. Recurring cases were counted as one case in which the most severe diagnostic of the case was included.

Re-evaluation of all cases slides were done according to British Society of Gastroenterology Guidelines 2005 for Barrett esophagus (table 1) and the degree of dysplasia was evaluated based on WHO Classification of tumours of the digestive system 2010 (Table 2). Histopathological evaluation was done by 2 researchers.

RESULTS

Based on archive data's in Pathology Anatomy Department of FKUI/RSCM during 2008-2012, there were 71 cases diagnosed with BE both histopathologically or clinically. There were 5 cases originated from 2 patients (1 patient undergo surveillance endoscopy twice, 1 other patient undergo surveillance endoscopy three times). BE cases were chosen based on the most severe diagnosis. One BE case did not fulfill the inclusion criteria, in which its clinical diagnosis was protuberance mass (not in accordance with BE) as well as 1 other case which slide could not be found (external review case). The result

Table 1. The reports of histopathological examination of Barrett esophagus or CLO based on BSG Guidelines 2005⁷

| Category | Reports | Histopathological Findings | Observation |
|----------|---|--|--|
| 1 | Diagnostic biopsy for CLO | The epithelial structure of true esophageal mucous is in line with metaplastic gland mucous, both columnar and pseudogoblet metaplasia or goblet | - |
| 2 | Biopsy supported the result of CLO endoscopy | Mucosal tissue with intestinal metaplasia with or without unorganized structure, villi architecture, mixed-metaplasia findings, etc | Might show incomplete intestinal metaplasia/ pseudogoblet findings in gaster, especially in hiatal hernia and cardia intestine metaplasia /CIM |
| 3 | Biopsy could be coherent with endoscopy but did not specified CLO | Gastric mucous in both fundal and cardia type without intestinal metaplasia. Mixed metaplasia tissues could still be found. | Might show transitional gastroesophageal or gastric findings, with or without hiatal hernia |
| 4 | Biopsy not CLO | Squamous epithelium without the presence of glandular epithelium | - |

Table 2. Classification of dysplasia findings based on WHO Classification of tumours of the digestive system 2010¹

| Category | Histopathology |
|-----------------------------|--|
| Negative for dysplasia | <p>Architecture Showed regenerative changes marked by crypts that are branched, germinated, atrophy, or cystic especially near or below ulceration</p> <p>Cytology Might be larger, hyperchromatic, true nucleolus, as well as light stratification of nucleus especially in the basis of the crypts. Nucleus-cytoplasm ratio could be 1:3 or 1: 4.</p> |
| Indefinite for dysplasia | Atypia is hard to establish when inflammations and ulcerations are present, as well as when the atypical changes could only be found on the basis of the crypt (stratification <1/3 cell thickness) with no surface involvement. |
| Low Grade Dysplasia | <p>Architecture Crypts are relatively normal or only minimally distorted contain cells with pencil-like atypical nuclei that are limited to the cell base.</p> <p>Cytology Elongated, enlarged, and crowded nuclei, hyperchromatic, irregular contour, dense chromatin with or without inconspicuous nucleolus, mild pleomorphic, mild alteration of cell polarity, mucin depletion, and increase mitosis. This stratification is limited to 1/3-2/3 cell thickness.</p> |
| High Grade Dysplasia | <p>Architecture Branched, germinated, dense crypts or viliform epithelium finding, sometimes intraluminal papils, cribriformis or bridges.</p> <p>Cytology True pleomorphic nuclei, inexistence of cell polarity, irregular nucleus membrane, increased nucleus-cytoplasm ratio, increased atypical mitosis especially at the upper crypt region, nucleus stratification in all crypt thickness as well as epithelial surface.</p> |
| Intramucosal Adenocarcinoma | Architecture Individual cells or small groups of gland with back-to-back arrangement inside lamina propria. Solid or cribriform growth pattern with expansion and distortion of surrounding crypts. Irregular glandular proliferation or hard distortion without previous glandular finding. |

of re-evaluation showed that 51 cases were BE, and the other 20 cases were not BE. There were 15 cases in which its early diagnosis was BE but then changed into non-BE, the other 5 cases were diagnosed as non-BE cases from the beginning. From the 15 cases, 10 cases were evaluated by the same pathologist, starting from

its early diagnosis, re-evaluation, and until its final diagnosis. The other 5 cases were diagnosed by a different pathologist, from its early diagnosis and the re-evaluation. The incidence of BE within 5 years could be seen in Figure 1.

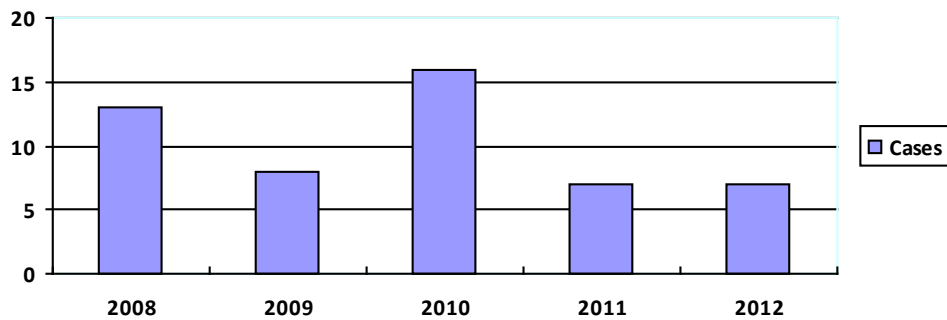


Figure 1. BE case frequency in Pathology Department of FKUI/RSCM from 2008-2012

Patients Characteristic

In this study, there were 51 cases in total, in which 18 cases occurred in female (35,3%) and 33 cases occurred in male (64,7%). Age distribution of BE patient range between 22 until 88 years

old, in which the mean of the age was 55 years old SD ±14,483. Dominant age group was 51-60 years old which had 15 cases (29,4%), followed with 41-50 years old and 61-70 years old with 10 cases (19,6%) respectively.

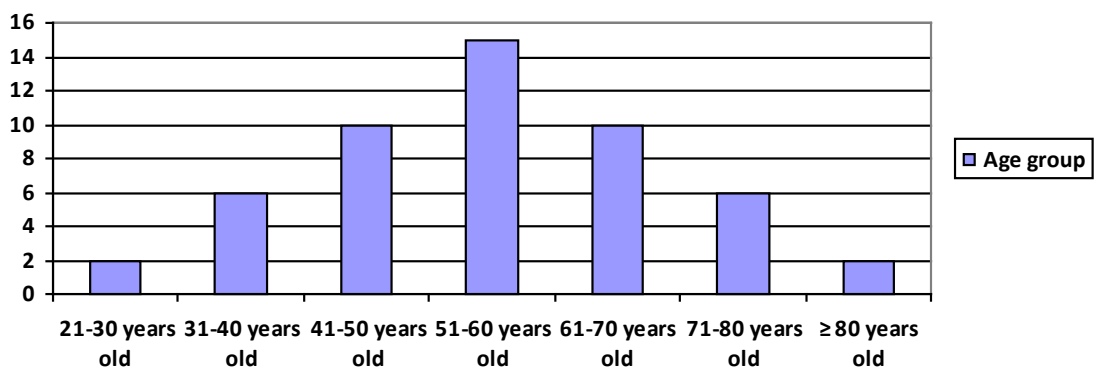


Figure 2. Age distribution of BE patients during 2008-2012.

Tabel 3. Demography, clinical, and endoscopy datas of Barrett Esophagus patients in Pathology Anatomy Departmen of FKUI/RSCM within 2008-2012.

| Demography, clinical, and endoscopy datas | | Total | % |
|---|-----------------------------|-------|-------|
| Gender | Male | 33 | 64,7 |
| | Female | 18 | 35,3 |
| Age group | 21-30 years old | 2 | 3,9 |
| | 31-40 years old | 6 | 11,76 |
| | 41-50 years old | 10 | 19,6 |
| | 51-60 years old | 15 | 29,4 |
| | 61-70 years old | 10 | 19,6 |
| | 71-80 years old | 6 | 11,76 |
| | ≥ 80 years old | 2 | 3,9 |
| Clinical | Esophagitis | 6 | 11,76 |
| | Esophagitis grade A | 2 | 3,9 |
| | Esophagitis grade B | 4 | 7,84 |
| | Esophagitis grade C | 4 | 7,84 |
| | Esophagitis grade D | 7 | 13,73 |
| | Barrett Esophagus | 17 | 33,3 |
| | SSBE | 2 | 3,9 |
| | Reflux esophagus | 1 | 1,96 |
| | Hiatal hernia | 4 | 7,84 |
| | Gastritis | 7 | 13,73 |
| | Pangastritis | 5 | 9,8 |
| | Suspected gastrophaty NSAID | 1 | 1,96 |
| | GERD | 2 | 3,9 |
| | Disphagia | 1 | 1,96 |
| | Dispepsia | 6 | 11,76 |
| | Melena | 2 | 3,9 |
| | Abdominal pain | 1 | 1,96 |
| Suspected malignancy | 2 | 3,9 | |
| Endoscopy | Esophagitis grade A | 2 | 3,9 |
| | Esophagitis grade B | 7 | 13,73 |
| | Esophagitis grade C | 15 | 29,4 |
| | Esophagitis grade D | 8 | 15,68 |
| | Esophagus Barrett | 16 | 31,37 |
| | SSBE | 3 | 5,9 |
| | Gastric erosion | 30 | 58,82 |
| | Pangastritis | 9 | 17,65 |
| | Hiatal hernia | 16 | 31,37 |
| | Bile Reflux | 3 | 5,9 |
| | Gastric ulcer | 3 | 5,9 |
| | Esophageal ulcer | 1 | 1,96 |
| | Stricture | 1 | 1,96 |
| | Suspected malignancy | 3 | 5,9 |

The results of endoscopy examination showed suspected BE cases in 16 cases (31,37%) and short segment barrett esophagus/SSBE finding in 3 cases (5,9%). As much as 32 cases (62,75%) of BE was found in conjunction with esophagitis, and 39 cases was found in conjunction with gastric erosion and pan-gastritis. Hiatal hernia was found in 16 cases (31,37%) and 3 cases (5,9%) was accompanied with bile reflux (Tabel 3).

The results of re-evaluation of BE dysplasia classification showed that 37 cases were non-dysplastic BE (Non Dysplasia/ND) (72,55%), 2 cases were BE indefinite /IND (3,9%), BE cases with dysplasia were found in 13 cases (25,5%), in which 11 cases were BE Low Grade dysplasia/

LGD (23,53%) and 1 case was BE High Grade dysplasia/HGD (1,97%). The hystopathological findings of BE cases based on BSG Guidelines showed that 76,47% of obtained BE cases had category 1 BE finding. Category 2 and 3 finding was only found in 6 BE cases (11,76%). (Figure 3-5).

As much as 15 cases was changed in diagnosis from BE ND to non -BE case (21,12%) in which 11 cases showed category 1 finding (73%). Two cases had category 3 presentation (13%), while category 2 and 4 were found in 1 case (7%). Clinical anotation as well as endoscopy result showed that 80% cases were accompanied by grade A-B esophagitis, 4 cases showed achalasia (26,7%) and 2 cases were accompanied by

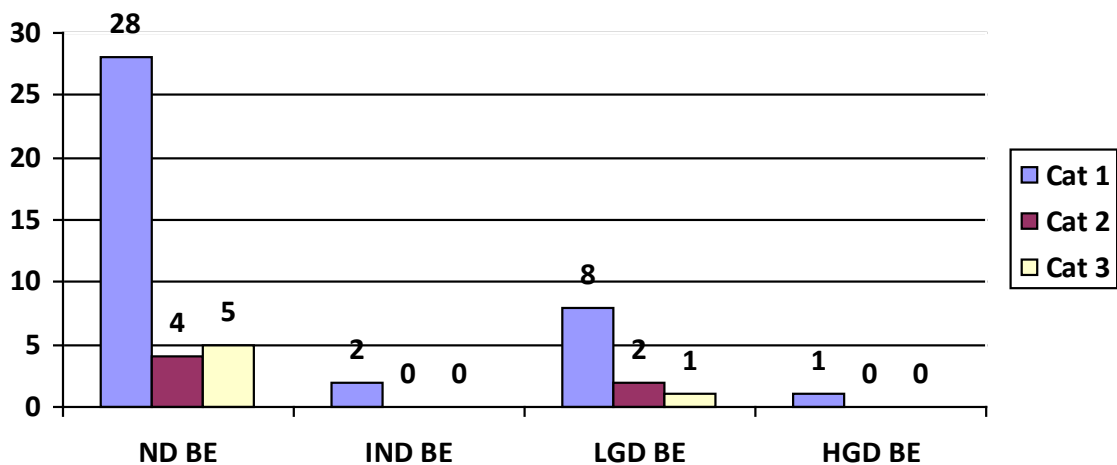


Figure 3. The number of BE cases related to dysplasia and histopathological finding based on BSG Guidelines.

esophageal stenosis (13,3%). There were 5 cases with both previous and review histopathological finding showed non-BE case with category 4 presentation. All of the results of endoscopy

examination in these cases showed a suspected BE case (100%) accompanied with esophagitis grade C-D in 3 cases (60%).

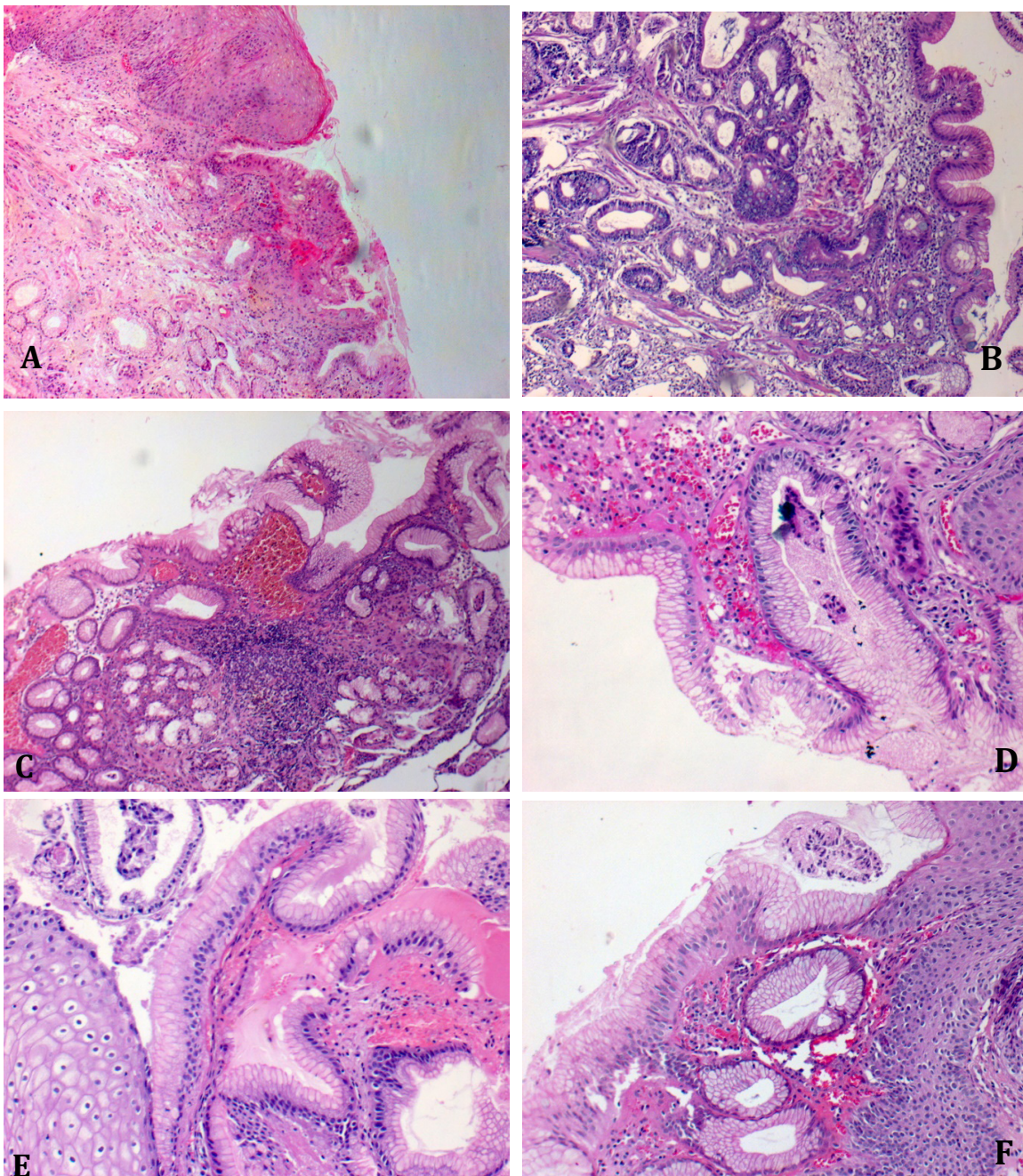


Figure 4. Histopathological presentation of BE based on BSG Guidelines and grade of dysplasia. (A) BE Category 1 presentation. Mucosal epithelial of esophagus with transitional squamocolumnar epithelium presentation which showed that esophageal squamous epithelium was in line with simple cylindrical epithelium undergoing MI. (B) BE Category 2 presentation. Mucosal epithelial of esophagus with simple cylindrical epithelium undergoing MI. No esophageal squamous epithelium could be seen. (C) BE Category 3 presentation. Mucosal epithelial of esophagus with simple cylindrical epithelium undergoing columnar metaplasia without MI. No esophageal squamous epithelium could be seen. (D) BE ND 200x magnification. Mucosal epithelial of esophagus with transitional squamocolumnar epithelium without dysplasia. (E) BE IND 200x magnification, Mucosal epithelial of esophagus with transitional squamocolumnar epithelium and cylindrical epithelium mucous showing $< \frac{1}{3}$ thickness localized stratification. (F) BE LGD 200x magnification, Mucosal epithelial of esophagus with transitional squamocolumnar and localized mucous cylindrical epithelium showing nucleus stratification

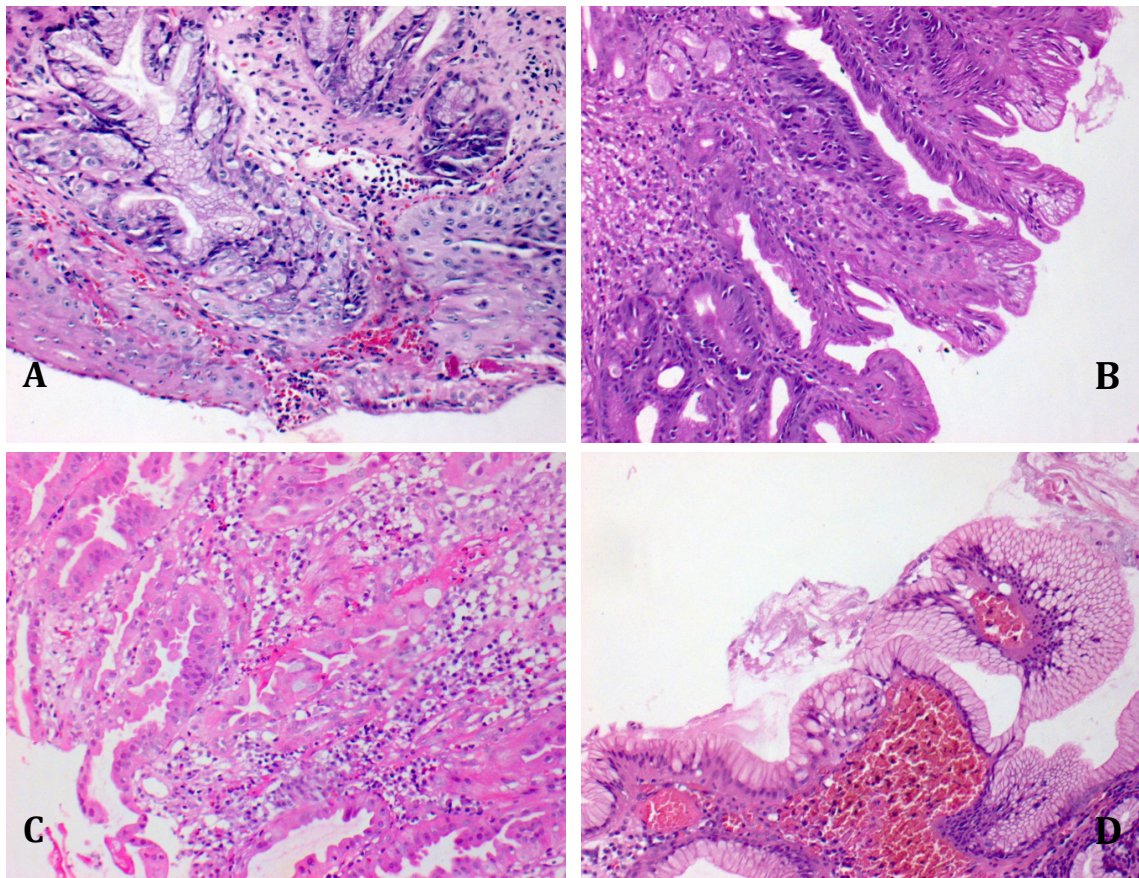


Figure 5. Histopathological presentation of BE based on BSG Guidelines and grade of dysplasia. (A) BE LGD 200x magnification. Mucosal epithelial of esophagus with transitional squamocollumnar epithelium with localized squamous epithellium going through moderate dysplasia. (B) BE LGD 200x magnification. Mucosal epithelual cells covered with simple cylindrical epithelium that shows cell stratification less than full cell thickness. (C) BE HGD 200x magnification. Hard glandular dysplasia of the glands at submucosal layer with dense glandular presentation, distortion, true pleomorphic nuclei, disappearing cell polarities, and increased nucleus-cytoplasmic ratio. Goblet cells could be seen in some cylindrical epithelium (MI). (D) BE ND with incomplete IM 100x magnification. Mucosal epithelial of esophagus with mucosal cylindrical epithelium accompanied by some pseudogoblet cells.

DISCUSSION

In this study we found that the prevalence of BE is higher in male patients (64,7%). The mean of patients age was 55 years old and the most popular age group was 51-60 years old. Some literature stated that the incidence of BE is higher in male patients within the age of 60-70 years old.^{4,5,14-16} Cited from another research that did endoscopy screening in patients who were suspected with colon cancer, it was stated that BE found in patients more than 50 years of age was not accompanied with reflux.³

Barrett Esophagus is found more often in patients with erosive esophagitis grade moderate-severe. Gilani et al. stated that the BE

was found in 27% patients who were suffering from erosive esophagitis grade moderate-severe.¹⁷ The length of erosive esophagitis segment found in endoscopy could also predict the length of BE on the next examination. In line with this study, it was found that 62,75% cases was accompanied with esophagitis, in which 71,86% (23/32) of them was moderate-severe esophagitis (C-D). The pathogenesis of erosive esophagitis into BE is currently still unclear. However some hypothesis stated that the damage of cells would be continued by healing and replacement of previous cells into columnar epithellium.

This study showed that, based on patients characteristic, 58,82% patients showed gastric erosion, while 17,65% showed pan-gastritis. Barrett Esophagus is widely known as the effect of prolonged acid-induced damages, started with the presence of erosive esophagitis and progressed into columnar and intestinal metaplasia. A research by Dixon et al stated that BE patients were found to be related to bile-induced gastritis.¹⁸

The presence of BE is related to patients with high acid reflux and severe bile reflux.¹⁹ Campos et al. found strong correlation between the presence of bile reflux with the occurrence of intestinal metaplasia.²⁰ This study found that 5,9% BE cases was accompanied with bile reflux.

Hiatal hernia was found in 16 BE cases (31,37%). Literatures stated that hiatal hernia is a common finding in patients with BE. One study showed that within 50 GERD patients who then suffered from BE, 63% of them also suffered from hiatal hernia. Another study found that the length of hiatal hernia was correlated with the severity of reflux which would affect the esophageal mucosal damage. Hiatal hernia would distort the transitional anatomical presentation of gastroesophagus, that normally could resist reflux, as well as altering the function of lower esophageal sphincter, causing an acidic hernia pouch to form between the diaphragm and the throat, and reducing peristaltic function.^{20,21}

The results of re-evaluation on the grade of dysplasia showed that non-dysplasia BE cases was found the most (72,55%). Groups with dysplasia were found 25,5%, in which LGD was found 23,53% and HGD was found 1,97%, while the other 2 cases were included in IND criteria (3,9%).

Patients with HGD has greater risk of progressing into adenocarcinoma. Some studies stated that the risk of adenocarcinoma in BE patients with HGD was 60% to 90%. The diagnosis of LGD showed lower risk, nonetheless it still has enough potential to progress into either HGD or adenocarcinoma, in which 20-28% LGD cases were reported to progress within 5 years. The determination of cancer risk in

patients with IND criteria is very difficult due to the high variability among evaluators, however there is one study that stated 14% cases of IND could progress into carcinoma.²

There are 15 cases of BE ND were changed into non-BE cases. Most cases (73%) showed category 1 characteristic which include transitional squamocolumnar epithelium with esophageal squamous epithelium located parallel to simple cylindrical epithelium without intestinal metaplasia. The inaccuracies of putting this finding into a BE case is due to its incompatibility with the results of EGD. Limited information given by clinicians is one of the reason of this inaccuracy. Often times, cases are presented without any information regarding EGD results. The follow up of all endoscopy results of all cases, evidently showed no indication to suspect BE, and only showed indication of grade A-B esophagitis, achalasia, and esophageal stenosis. Because these findings might show typical BE presentations, these cases were directly diagnosed as BE without considering the results of EGD, even though these findings could easily be found in normal healthy transitional gastroesophagus area.

Basically, the possibility of BE diagnosis in these cases were still suitable if clinician was suspecting BE based on the indications found in endoscopy results, especially if the endoscopy were performed in the right area of biopsy, which should be ≥ 2 cm above the gastroesophagus transitional area. BE could still be diagnosed even when the area of biopsy was located ≤ 3 cm above the gastroesophagus transitional area, also called as SSBE. However, the information from endoscopy results did not lead into BE, thus BE diagnosis could not be made.

One case was diagnosed as BE with category 2 finding in which mucous epithelium was covered by simple cylindrical epithelium accompanied with MI. The inaccuracy of classifying this finding into BE case was because this finding showed MI (Cardia Intestine Metaplasia /CIM) of transitional gastroesophageal area. In addition to that, there were also incompatibility between histopathological finding with EGD results, in

which EGD results showed Grade A esophagitis with no indication of BE.

In the past the presentation of CIM was considered a Ultra-Short Segment Barrett Esophagus/USSBE and, even until now, there were still some people who uses this term to describe an intestinal metaplasia of esophagus that could not be detected from endoscopy examination. CIM could also be found in 16-35% biopsy of normal gastroesophageal transitional area.⁸ Many researches stated different entities between SSBE and CIM. Short Segment Barrett Esophagus is related to a chronic reflux history, while CIM is related to corpus and antral gastritis.^{22,23} Due to limited information about its potential of developing into neoplasm, it is recommended not to perform biopsy in normal gastroesophageal transitional area and not to use the term CIM in routine diagnosis.⁸

Two case had category 3 (13%) presentations, in which the mucous epithellium was covered with simple cylindrical epithellium without the presence of MI. These presentations might be either BE or a normal gastroesophageal transitional area, or even normal gaster. The results of EGD showed achalasia and grade A-B esophagitis. This incompatibility makes both case could not be diagnosed as BE.

One other case showed category 4 presentation, in which the esophageal mucous epithelium was not accompanied with simple cylindrical epithellium but was evaluated as a reflux esophagitis with the possibility of BE. The results of re-evaluation showed no indication of possible BE case.

Five cases showed only the presence of esophageal mucous epithellium (category 4) in both evaluation and re-evaluation, even though the results of endoscopy suspected the presence of BE. Even though the result of endoscopy supported the indication of BE, the results of biopsy showed no sign of BE, thus the diagnosis of BE could not be made. This might be due to sampling error in locating the transitional area of gastroesophagus because the length of the transitional segment is quite varied and could be affected by breathing. The accuracy of locating

transitional area of gastroesophagus is very important, because there are a lot of suspected BE cases that are in fact SSBE.²¹

CONCLUSION

The prevalence of BE was found most in 41-50 years old age group. The mean of patients age was 55 years old and was predominated by male (64,7%). The results of re-evaluation of dysplasia classification showed BE ND cases were 72,55%; BE IND cases were 3,9%; BE LGD cases were 23,53%; and HGD cases were 1,97%.

The diagnosis of BE could be made if endoscopy examination showed indication of BE, confirmed by histopathological examinations in which BE presentations was found, either in category 1, 2 or 3. Changes in diagnosis from BE ND into non-BE case was found 21,12%. The inaccuracy of diagnosis was caused by limited informations of EGD results given in patients form.

If there are any indication of BE or SSBE in cases with category 1-3 presentations with limited information of EGD results, then it is recommended to mention the possibility of Barrett Esophagus accompanied with an inquiry to ensure that the biopsy was done \geq 2 cm above gastroesophageal transitional area. Cases with clinical indication of BE but had no BE presentations in biopsy results, might be caused by an inaccuracy of biopsy sampling. Thus, it is recommended to put a recommendation inquiry for a follow up endoscopy.

Due to the importance of compatibility between the results of endoscopy as well as histopathological examination in the diagnosis of BE, it is hoped that patients information could be more comprehensive, either in the form of clinical presentation of the patients, as well as the results of EGD and the location of the biopsy, in the patients reference form.

REFERENCES

1. Flejou JF, Odze RD, Montgomery E, Chandrasoma P, Hofler H, Boffetta P, et al. Adenocarcinoma of the oesophagus. In: Bosman FT, Carneiro F, Hruban RH, Theise

- N, editors. World Health Organization classification of tumours of the digestive system. Lyon: IARC Press. 2010. 25-31.
2. Voltaggio L, Montgomery EA, Lam-Himlin D. A clinical and histopathologic focus on Barrett esophagus and Barrett-related dysplasia. *Arch Pathol Lab Med.* 2011;135:1249-60.
 3. Chang JT, Katzka DA. Gastroesophageal reflux disease, Barrett esophagus, and esophageal adenocarcinoma. *Arch Intern Med.* 2004; 164:1482-8.
 4. Switzer-Taylor V, Schlup M, Lubcke R, Livingstone V, Schultz. Barrett's esophagus: a retrospective analysis of 13 years surveillance. *J Gastroenterol and Hepatol.* 2008;23:1362-7.
 5. Alcedo J, Ferrandez, Arenas J, Sopena F, Ortego J, Sainz R, et al. Trends in Barrett's esophagus diagnosis in Southern Europe: implications for surveillance. *Dis Esophagus.* 2009;22:239-48.
 6. Wang KK, Sampliner RE. Updated guidelines 2008 for the diagnosis, surveillance and therapy of Barrett's Esophagus. *Am J Gastroenterol.* 2008;103:788-97.
 7. Watson A, Heading RC, Shepherd NA. Guidelines for diagnosis and management of Barrett's columnar-lined oesophagus. In: Watson A, Heading RC, Shepherd NA, editors. *Guidelines for diagnosis and management of Barrett's columnar-lined oesophagus.* Leicestershire: British Society of Gastroenterology; 2005. 1-3.
 8. Shepherd, NA. Barrett's oesophagus. In: Shepherd NA, Warren BE, Williams GT, Greenson JK, Lauwers GY, Novelli MR, editors. *Morson and Dawson's gastrointestinal pathology.* 5th edition. West Sussex UK: Blackwell Publishing Ltd; 2013. 39-48.
 9. Revisi konsensus nasional penatalaksanaan penyakit reflux gastroesophageal (Gastroesophageal reflux disease/GERD) di Indonesia. In: Syam AF, Aulia C, Renaldi K, Simadibrata M, Abdullah M, Tedjasaputra TR, editors. *Jakarta: Perkumpulan Gastroenterologi Indonesia (PGI);* 2013. 1-20.
 10. Sharma P, Dent J, Armstrong D, Bergman JJGHM, Gossner L, Hoshihara Y, et al. The development and validation of an endoscopic grading system for Barrett's esophagus: the prague C & M criteria. *Gastroenterol.* 2006;131:1392-9.
 11. Goldblum JR. Barrett's esophagus and Barrett's-related dysplasia. *Mod Pathol.* 2003;16:316-24.
 12. Barr H, Shepherd NA. The management of dysplasia. In: Watson A, Heading RC, Shepherd NA, editors. *Guidelines for diagnosis and management of Barrett's columnar-lined oesophagus.* Leicestershire: British Society of Gastroenterology; 2005. 32-6.
 13. Montgomery E, Bronner MP, Goldblum JR, Greenson JK, Haber MM, Hart J, et al. Reproducibility of the diagnosis of dysplasia in Barrett esophagus: a reaffirmation. *Hum Pathol.* 2001;32:368-78.
 14. Van Zanten SJOV, Thomson ABR, Barkun AN, Armstrongs D, Chibas N, White RJ, et al. The prevalence of Barrett's oesophagus in a cohort of 1040 Canadian primarycare patients with uninvestigated dyspepsia undergoing prompt endoscopy. *Aliment Pharmacol Ther.* 2006; 23:595-9.
 15. Kula Z, Weishof. The prevalence of Barrett's oesophagus in own material of 6326 endoscopies. *Gastroenterologia Polska.* 2007; 14:85-9.
 16. Moayyedi P, Naylor G. Epidemiology of columnar-lined oesophagus. In: Watson A, Heading RC, Shepherd NA, editors. *Guidelines for diagnosis and management of Barrett's columnar-lined oesophagus.* Leicestershire: British Society of Gastroenterology; 2005. 7-9.
 17. Gilani N, Gerkin RD, Ramirez FC, Hakim S, Randolph AC. Prevalence of Barrett's esophagus in patients with moderate to severe erosive esophagitis. *World J Gastroenterol.* 2008; 14:3518-22.
 18. Dixon MF, Neville PM, Mapstone NP, Moayyedi P, Axon ATR. Bile reflux gastritis and Barrett's oesophagus: further evidence of a role for duodenogastro-oesophageal reflux? *Gut.* 2001; 49:359-63.
 19. Milind R, Attwood SE. Natural history of

- Barrett's esophagus. *World J Gastroenterol*. 2012; 18:3483-91.
20. Campos GMR, DeMeester SR, Peters JH, Oberg S, Crookes PF, Hagen JA. Predictive factors of Barrett esophagus. *Arch Sur*. 2001; 136:1267-73.
 21. Modiano N, Gerson LB. Barrett's esophagus: incidence, etiology, pathophysiologi, prevention, and treatment. *Ther and Clin Risk Manag*. 2007; 3:1035-45.
 22. Van Sandick JW, Van Lanschot JB, Van Felius L, Haringsma J, Tytat GNJ, Dekker W, et al. Intestinal metaplasia of the esophagus or esophagogastric junction. *Am J Clin Pathol*. 2002; 117:117-25.
 23. Chang Y, Liu B, Liu GS, Wang T, Gong J. Short-segment Barrett's esophagus and cardia intestinal metaplasia: a comparative analysis. *World J Gastroenterol*. 2010; 16:6151-4.