

Multiple intracranial tuberculomas: A rare case of CNS TB

Agus Nur Salim Winarno*¹

¹Emergency Physician at R.Koesma General Hospital Tuban, Indonesia

Case Report

ABSTRACT

ARTICLE INFO

Keywords:

Tuberculosis,
CNS TB,
Intracranial Tuberculoma

*Corresponding author:

agusnur_salim@yahoo.com

DOI : 10.20885/JKKI.Vol9.Iss1.art10

History:

Received: June 30, 2017

Accepted: April 24, 2018

Online: April 30, 2018

Copyright ©2018 Authors.
This is an open access article
distributed under the terms
of the Creative Commons At-
tribution-NonCommercial 4.0
International Licence (<http://creativecommons.org/licenses/by-nc/4.0/>).

Tuberculosis (TB) still continues to remain a major health problem worldwide, with at least 8.6 million cases occur in 2012. TB doesn't mainly affect the lungs but it can affect the extra pulmonary system. Central nervous system (CNS) is one complication of TB that should be a concern as it is associated with high morbidity and mortality. Tuberculoma is a rare CNS TB and challenging in diagnostic. It will be presented a case of an adult female with history of on-going TB treatment that presents with altered mental status, focal neurological signs and increased ICP signs and symptoms. The head CT with contrast revealed a lesion resembling a brain tuberculoma. She was admitted to ICU and she got anti-TB drugs and systemic steroid.

Tuberkulosis (TB) masih menjadi salah satu masalah kesehatan di dunia. Sekitar 8,6 juta kasus terjadi pada tahun 2012. TB tidak hanya mempengaruhi paru-paru saja, tetapi juga mempengaruhi sistem ekstrapulmoner. Salah satu komplikasi yang harus diperhatikan ialah TB pada sistem saraf pusat (CNS TB). Jenis TB ini berkorelasi dengan tingginya angka morbiditas dan mortalitas. Tuberkuloma adalah salah satu bentuk CNS TB yang jarang dijumpai dan cukup menantang untuk dapat terdiagnosa. Artikel ini menyajikan sebuah kasus wanita dewasa dengan penurunan kesadaran. Diketahui bahwa pasien sedang dalam pengobatan TB, didapatkan juga adanya tanda neurologis focal dan tanda serta gejala peningkatan tekanan intrakranial. CT scan kepala dengan kontras menunjukkan adanya gambaran tuberkuloma.

INTRODUCTION

Tuberculosis (TB) remains continue as the main health problem until today. It is estimated that about 8,6 million cases occurred in 2012. Most of them occur in Asia and Africa (58% and 27% respectively). It's prevalence is about 169 per 100.000 population. TB was also one of the world's deadliest disease. It's mortality is about 1,3 million deaths in 2012.¹ In Indonesia, the incidence of TB is 1.020.000 people in 2015 (395 per 100.000 population). Indonesia is also

listed as one of the high-burden countries of TB in the world.² Tuberculosis is an infectious disease caused by bacteria called *Mycobacterium tuberculosis* (an acid-fast-rod-shaped bacterium). TB is an airborne disease that infects via droplets expelled by the person who has TB by cough, speaking or sneezing.³ It primarily affects the lungs. But, the disease can also affect other organs. TB can involve the musculoskeletal system, abdominal organ, cutaneous and central nervous system. Central nervous system (CNS)

TB is a serious form of extrapulmonary TB. It affects 5-10% of patients with pulmonary TB.⁴ It can form lesions in the brain either tuberculoma or tuberculous abscess.⁴ It can also infect the meningeal layers and causing meningitis TB. Among them, intracranial tuberculoma is the least common presentation that accounts 1% of the patients.⁵ The diagnosis and management of intracranial tuberculoma are also challenging as it has a wide range of clinical manifestation and differential diagnosis. In this article we describe the case of a patient with multiple intracranial tuberculoma. The CT scan of the patient is quite breathtaking. In these article we also discussion about how to diagnose tuberculoma and its

management.

CASE DESCRIPTION

A 43-year-old female was brought to the emergency room (ER) with a decrease of consciousness. It's been about 5 days the patient complained about his headache, nausea and vomiting which was getting worse. She was only lying down in her bed since she was very weak and she could not move her right extremities. She also could not speak fluently and her visions were blurred. No seizure happened at home. Past history obtained from her husband revealed that she had a "brain disease" which has been diagnosed 3 months ago. She was consuming a

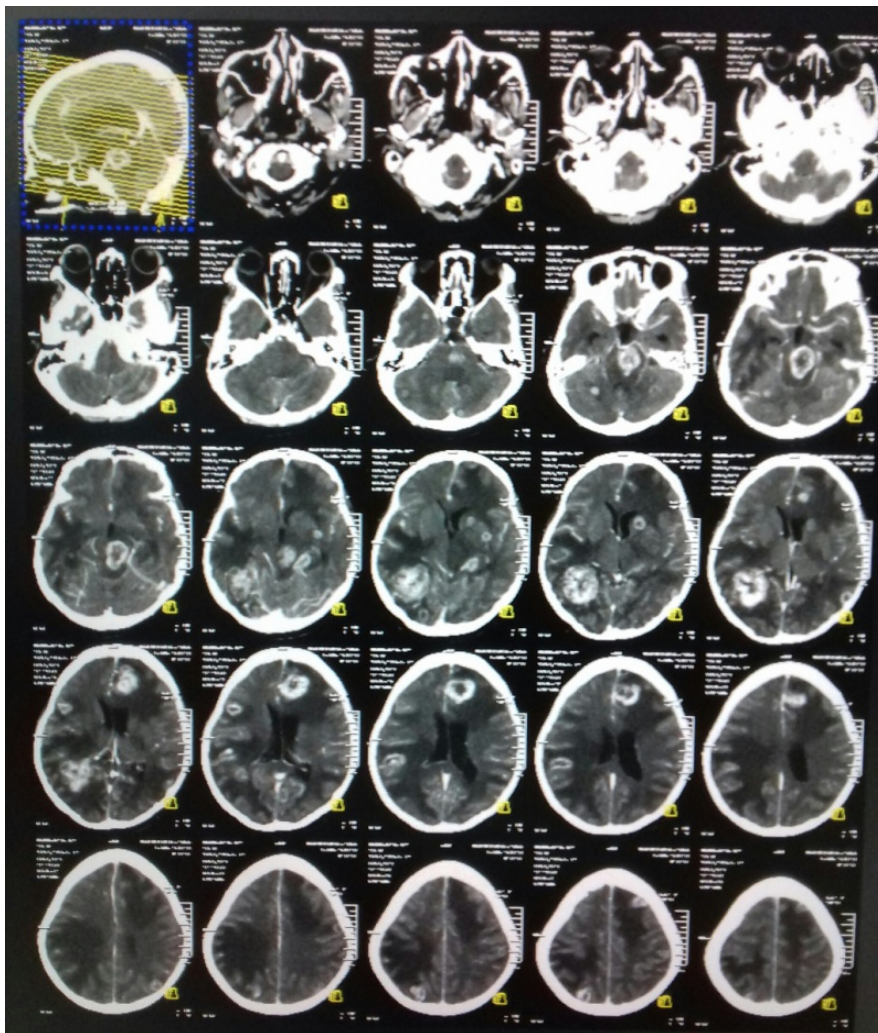


Figure 1. Patient's head CT with contrast shows multiple ring enhancement with perilesional edema

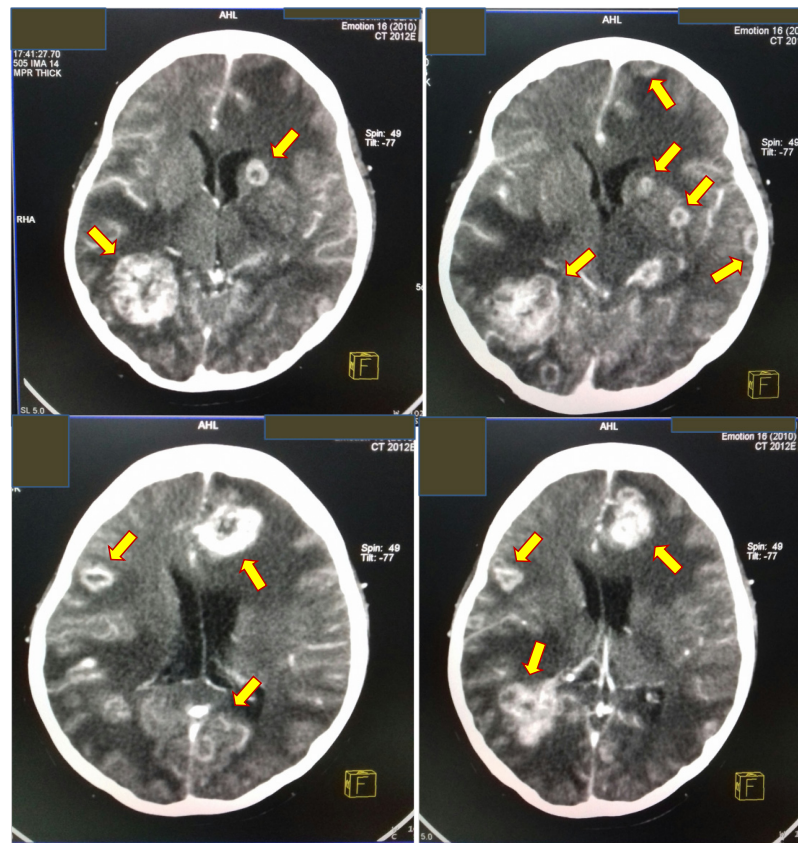


Figure 2. Brain tuberculomas (yellow arrows) with surrounding edema destroy the brain and cause midline shift

daily fixed-dose combination (FDC) drug since several months ago. The drug is tuberculosis (TB) regiment. The patient was in the third month of treatment and she was consuming 4 tablets of 4FDC per day. The 4FDC consists of INH 75 mg; rifampicin 150 mg; pyrazinamide 400 mg; ethambutol 275 mg. The patient had also accepted daily 1 gram of streptomycin injection for 2 months. About one year ago, she was diagnosed with pulmonary TB but she missed the medication for several months (drop out TB case).

The glasgow coma scale (GCS) of the patient is E2V3M5. She looked weak. Blood pressure was 140/100 mmHg; pulse: 84 x/min; respiration: 28 x/min; temperature : 37,20C; Sat O2: 96% in room air. She was not anemic, her lungs were clear, no murmur listened, her abdomen was soft, non-tender and her extremities were warm, no edema found. The neurological exam showed anisocoria pupil (3 mm/5 mm) and

right lateralizing. Babinski sign is negative. Her electrocardiogram (ECG) was sinus tachycardia. The laboratory revealed leukocytosis (21.000 cell/mm³) and elevated liver enzyme (SGOT 47 U/L; SGPT 157 U/L). Other labs (RFT, random glucose, electrolytes) were normal. Then, she underwent head CT with contrast using iopamidol. The CT showed multiple ring contrast enhancement in right and left cerebral hemisphere, mesencephalon, cerebellum, and left basal ganglia. Perifocal edema can be found around the lesions with a right ventricle occupied and also a significant midline deviation (see Figure 1 and 2). All of them are consistent with multiple intracranial tuberculomas. Then, the patient was admitted to the intensive care unit (ICU). In the ICU, the patient received the injection of dexamethasone 5 mg q8h i.v. injection, ranitidine 50 mg q12h i.v. injection, metamizole 500 mg q8h i.v., 4 tablets of 4FDC q24h p.o., 1 tablet of B6 q24h p.o., 1 tablet of

Curcuma q12h p.o. The second day, the patient was getting worse, she received cardiac and ventilation support. But, the patient did not survive. She was passed away on the second day of treatment.

DISCUSSION

Intracranial tuberculoma is a one of CNS tuberculosis. Tuberculosis is an infectious disease that mainly involves pulmonary system, but in a certain condition, it can go out to extrapulmonary.⁶ The involvement of TB into CNS is uncommon (only 5-10% in a patient with pulmonary TB).^{4,6} It needs awareness as it relates to a high morbidity and mortality. Clinically, it can manifest as meningitis, cerebritis, tuberculoma, and abscess (see Table 1).^{5,6} Among them, tuberculoma is the rarest.⁵

Table 1. CNS TB classification⁹

Intracranial TB
<ul style="list-style-type: none"> • Tuberculoma (single or multiple) • Tuberculous meningitis • Tuberculous encephalopathy • Tuberculous vasculopathy • Tuberculous brain abscess
Spinal TB
<ul style="list-style-type: none"> • Pott’s spine and Pott’s paraplegia • Non-osseus spinal tuberculoma • Spinal meningitis

Tuberculoma is granulomatous tissue that forms intracranial space-occupying mass.⁷ Tuberculoma can reside in intracranial (most common) and in spinal. Tuberculoma results from hematogenous dissemination from the focus of tuberculous infection in another part of the body.^{5,7} The object from the origin site of infection called as tubercle travels to the CNS and joins together to form a mature tuberculoma.⁷ Mature tuberculoma consists of a central zone of caseation necrotic tissue surrounded by a

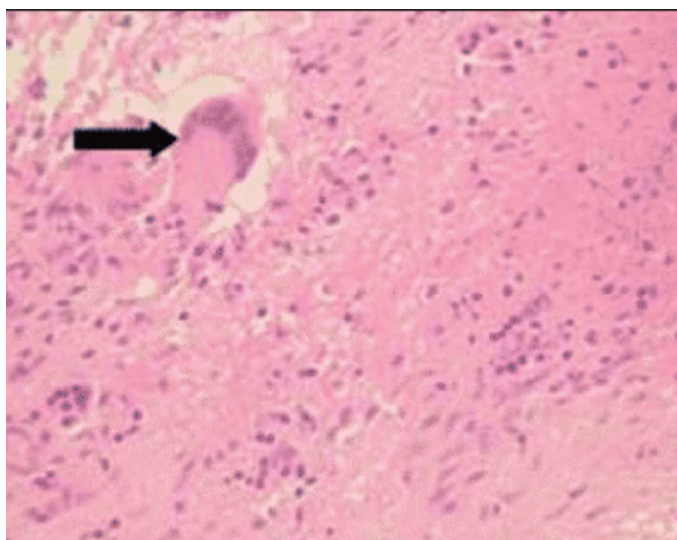


Figure 3. The histology feature of brain tuberculoma shows granulomatous reaction, Langhans giant cell (black arrow) with caseous necrotic(H&E staining).¹⁰

capsule built from fibroblasts, epithelioid cell, Langhans giant cells, and lymphocytes(Figure 3)^{7,8}. In the initial stage, there is an inflammatory reaction with the presence of giant cells. In that stage, the capsule is poor of collagen. In the later stage, the inflammation subsides and the capsule

becomes rich in collagen.⁷

Diagnosis of tuberculoma is difficult and challenging. It’s because tuberculoma has an insidious, unspecific signs and symptoms and also its imaging can mimic with other space-occupying lesion (ex. pyogenic abscess).¹¹ Tuberculoma

should be considered in TB patient who presents with altered mental status, focal neurology signs, or increased intracranial pressure (ICP).¹² The signs and symptoms of increased ICP include a headache, vomiting, convulsions, blurring of visions and papilledema.¹³ The clinical feature of tuberculoma spans from subtle to severe illness. It depends on the time of presentation, location, and size of the lesion.^{6,8,13} In the initial stage, there may be no clinical feature or asymptomatic, later it emerges features like a headache and epilepsy. If the patient presents in delayed condition, there will be increased ICP and weakness of extremities.⁸ In this case, the patient presents with a headache, nausea, vomiting and weakness of her extremities which suggest delayed presentation. Other clinical features are influenced by the location of the lesion. The lesion in cerebrum or cerebellum can cause lateralizing signs. Periorbital edema causes somnolence.¹³ A clinician should also

pay attention to the symptom of seizure. It is probably to be the main feature of intracranial tuberculoma.^{11,13}

Diagnosis of tuberculoma is constructed clinically and it needs additional examination. Past history of the patient could be a great value to help to construct the diagnosis.¹³ Recent imaging facilities like CT and MRI can enhance the certainty of the diagnosis. The role of CT or MRI as neuroimaging in the diagnosis of tuberculoma has been established in various trials.⁸ CT is reported to have a sensitivity of 100% and a specificity of 85.7%. MRI is reported superior to CT in diagnosis of tuberculoma, but its availability should be a concern.¹⁴ Its superiority is in visualizing the morphological detail of tuberculoma, especially in the tiny lesion in the brain stem.⁸ In conclusion, both of them is essential to support the diagnosis of brain tuberculoma.¹⁴ In this case, the supporting diagnostic modality uses CT because there is no

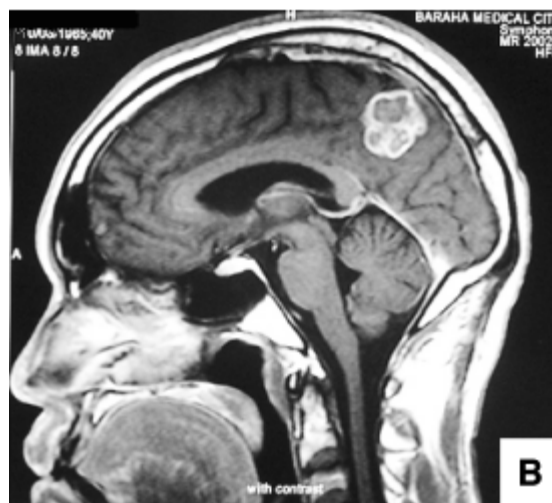


Figure 4. MRI T1-weighted with gadolinium enhancement shows isointense lobulated tuberculoma.⁸

MRI available.

CT of intracranial tuberculoma will show enhancing mass lesion.¹³ The enhancing lesion can possibly mimic other diagnoses such as glioma, metastatic tumor, abscess, cysticercosis, and other granulomas. The further diagnostic process is advised using MRI diffusion-weighted

imaging, spectroscopy or minimally invasive CT-guided biopsy.⁸ Tuberculoma in MRI will show a conglomerated ring-enhanced mass on gadolinium-enhanced T1-weighted images (Figure 4).⁷ MRI will also distinguish the lesion of tuberculoma with others with T1 and T2 based on its nature, either caseating or non-caseating.

Tuberculoma is distinguished with others in its lower T2-weighted as it contains more lipid.¹¹ In our case, we use CT with contrast to strengthen the diagnosis which shows multiple ring enhancement. It is also connected with the clinical data from the patient that she suffered from altered mental status, increased ICP signs, and the past history of TB with on-going anti-TB drugs.

The treatment of tuberculoma is with the continuation of anti-TB drugs with the addition of high dose steroid.^{12,13} The Anti-TB drugs consist of INH (5 mg/kg), Rifampicin (10 mg/kg), Pyrazinamide (15-30 mg/kg) and Ethambutol (15-25 mg/kg). These drugs are taken for first 2 months, then the next 4 months patient takes INH (5 mg/kg) and rifampicin (10 mg/kg). The duration of treatment can be prolonged for 18 months if the response is slow, culture remains positive in the extended period and the patient doesn't take pyrazinamid in the first 2 month.¹³ Center for Disease and Control (CDC) recommends 12 months of treatment.⁵ It is also suggested that the duration of treatment should be tailored to the radiological response.⁵ Follow up with radiological exam (preferred MRI) must be made in 1 month, 3 months, and 6 months after the diagnosis is made and the treatment is started.¹¹

Systemic corticosteroid can be given if there is perilesional edema or paradoxical progression.^{5,13} It is given as adjuvant therapy. The mechanism of steroid is by controlling the systemic effect of TNF, INF and other immune mediators. It also suppresses the hypersensitivity of tubercular protein. Dexamethasone 6-12 mg/day or prednisone 60-80 mg/day can be given to the patient.¹³ Surgical therapy is indicated in the patient with increased ICP even with medical treatment, seizure that is unresponsive with anticonvulsant and compression symptoms.¹¹ Another indication is if there are uncertain diagnosis.⁵ In our case, patient is treated with anti-TB drugs in FDC form via NG tube as the consciousness is altered. The patient had also systemic steroid (dexamethasone injection). But, the disease is too severe. The tuberculoma

is multiple and it causes compression that is possibly to the brainstem. She didn't make it after she had ventilation and cardiac support.

CONCLUSION

Tuberculoma should be considered in TB patient with altered mental status, focal neurological signs and increased ICP signs and symptoms. In order to strengthen the diagnosis, CT and MRI can be performed. Treatment includes continuation of anti-TB drugs and addition of systemic steroid.

CONFLICT OF INTEREST

We declare there is no conflict of interest

ACKNOWLEDGEMENT

Non declare

REFERENCES

1. Sulis G, Alberto R, Alberto M, Mario CR. Tuberculosis: Epidemiology and control. *Mediterranean Journal of Hematology and Infectious Diseases*. 2014;6(1):e2014070.
2. World Health Organization. Global tuberculosis report 2016 [Internet]. 2016. Available from: <http://www.who.int>
3. Singer-Leshinsky S. Pulmonary tuberculosis: Improving diagnosis and treatment. *American Academy of Physician Assistants*. 2016;29(2):20-5.
4. Vidal JE, Adrian VH, Augusto CPO, Alexandre LS, Geraldine M, Paula RMS, et al. Cerebral tuberculoma in AIDS patients: A forgotten diagnosis? *Arquivos de Neuro-Psiquiatria*. 2004;62(3-B):793-6.
5. Monteiro R, Jose CC, Claudia C, Raquel D. Cerebral Tuberculomas- A clinical challenge;9:. <http://dx.doi.org/>. *Respiratory Medicine Case Reports*. 2013;9:34-7.
6. Malhotra A, Mini M. Giant cerebral tuberculoma in pregnancy: Review of literature discussion. *International Surgery Journal*. 2016;3(1):386-9.
7. Chattarjee S. Brain Tuberculomas, Tubercular meningitis, and post-tubercular hydrocephalus in children. *Journal of Pediat-*

- ric Neurosciences. 2011;6(1):S96–100.
8. Kim TK, Kee HC, Chong JK, Jin MG, Myeong CK, Moon HH. Intracranial tuberculoma: Comparison of MR with pathologic findings. *American Journal of Neuroradiology*. 1995;16(9):1903–8.
 9. Idris MNA, Sokrab TEO, Arbab MAR, Ahmed AEM, El-Rasoul H, Ali S, et al. Tuberculoma of the brain: A series of 16 cases treated with anti-tuberculosis drugs. *International Journal of Tuberculosis and Lung Disease*. 2007;11(1):91–5.
 10. Patnaik A, Sudhansu SM, Satya BS. Surgical management of double giant Tuberculomas of brain involving both supratentorial and infratentorial compartments. *Journal of Pediatrics Neurosciences*. 2013;8(1):84–5.
 11. Banderas ME, Perez GV, Alonso MR, Ruiz MJ, De Pablo GA. Cerebral tuberculoma in a lung transplant patient. *Journal of Microbial & Biochemical Technology*;7(5):2015;7(5):244–7.
 12. Rajakaruna PDG. Cerebral tuberculoma;61:922. *Thorax*. 2006;61(10):922.
 13. Ashok-Kumar EA, Jijiya-Bai P. Clinical Study of CNS Tuberculomas. *International Archives of Integrated Medicine*. 2016;3(6):101–6.
 14. Saleh M, Ali AS, Ali AP. Brain Tuberculomas: A case report. *Jundishapur Journal of Microbiology*. 2014;7(7):e11252.